

Poster abstracts

Id: BTS-5

Topic: Aesthetic Dermatology

Keloids, hypertrophic and atrophic scars – What's new in treatment Technologies

Olga Zabnenkova

Presentation type: Poster

Keloid and hypertrophic scars are a cutaneous condition characterized by deposits of excessive amounts of collagen which gives rise to a raised scar, but not to the degree observed with keloids. Like keloids, they form most often at the sites of pimples, body piercings, cuts and burns. They often contain nerves and blood vessels. They generally develop after thermal or traumatic injury that involves the deep layers of the dermis and express high levels of TGF- β .

Also mechanical tension on a wound has been identified as a leading cause for hypertrophic scar formation. Although possible outcomes of the inflammatory acne lesions are acne scars which, although they can be treated in a number of ways. The main types of acne scars are atrophic and hypertrophic scars. The pathogenesis of acne scarring is still not fully understood, but several hypotheses have been proposed. There are numerous treatments: chemical peels, fractional laser treatment, microdermabrasion, needling, RF fractional thermolysis & HA filler injections and combined therapies for atrophic scars; silicone gels, intralesional steroid therapy combined with BTNoA, cryotherapy for hypertrophic and keloidal lesions.

Id: BTS-6

Topic: Dermal filler treatment

Restoration and beatification of perioral area. How to create appealing lips

Olga Zabnenkova

Presentation type: Poster

Lips are one of the most attractive and variable features of a face. The shape and size of the lips are influenced by genetic factors that determine shape and volume of the lips, as well as shape of the jaws and dental occlusion. They are also influenced by individual factors, such as muscle activity patterns, bad habits, dental arch integrity, etc.

Lip contouring is done for restoration and beautification of lip contour and volume as well as of the whole perioral area (barcode lines, marionette lines, nasolabial folds).

Correction techniques are varied. Each patient needs an individual approach. We have suggested several variants of lip augmentation for orthocheilia, microcheilia, narrow or asymmetrical lips.

To correct lip aging (involution), when not only volume loss, but barcode lines and marionette lines have to be treated, we recommend to combine BoTN with HA fillers, mesothreads, Fraxel and/or other methods.

Materials and methods

Material: 50 female patients (24-63 years old)

Methods of treatment: HA fillers, BTA, meso threads

Results

Individual approach to lip augmentation that accounts for specific age and anatomy features of the lips and perioral area, focused on proportions, can help to produce a perfectly natural effect.

Conclusions

HA filler injections remain to be the main method of restoration and beautification of the lips and perioral area.

In case of visible aging signs a combination of HA fillers, BTA and meso threads is recommended.

Poster abstracts

Id: BTS-7

Topic: Abdominoplasty

Evaluation of the neo-umbilicus cutaneous sensitivity following abdominoplasty

Sensitivity and neo-umbilicus

Mathias Tremp¹, Wenjin Wang², Carlo M. Oranges¹, Dirk J. Schaefer¹, Wang Wei², Daniel D. Kalbermatten^{*}

- (1) Department of Plastic, Reconstructive, Aesthetic and Hand Surgery, University Hospital Basel, Spitalstrasse 21, 4031 Basel, Switzerland
- (2) Department of Plastic and Reconstructive Surgery, Shanghai Ninth People's Hospital, Shanghai JiaoTong University, School of Medicine, Shanghai, China

Presentation type: Poster

Background

Abdominal cutaneous sensitivity loss after abdominoplasty is an undesirable outcome. However, little is known in the literature about sensitivity changes of the neo-umbilicus after abdominoplasty. The aim of this study was to evaluate post-abdominoplasty cutaneous sensitivity of the neo-umbilicus using clinical, quantitative, and reproducible methods.

Methods

Patients who underwent abdominoplasty were included, whereas the control group consisted of healthy volunteers with similar demographic characteristics but who did not undergo abdominoplasty. The umbilicus was divided into five zones (Figure 1), and superficial tactile sensitivity and spatial orientation were assessed subjectively (score 1-4) and objectively (Semmes-Weinstein monofilament examination).

Results

20 patients (45 ± 12 years) operated on consecutively between April 2012 and May 2016 and 14 healthy volunteers in the control group (39 ± 9 years) could be included. Although there were statistically significant differences ($p = 0.0005$) in the average cutaneous pressure thresholds between the control group (0.4 g/mm^2 , range $0.07 - 2 \text{ g/mm}^2$) and the study group (0.4 g/mm^2 , range $0.07 - 4 \text{ g/mm}^2$), patient satisfaction after a mean follow-up of 33 ± 16 months (range 10 - 62 months) was acceptable (mean satisfaction score 1.8 ± 0.7). Furthermore, spatial perceptions were precise in all patients and similar to the control group.

Conclusion

Our long-term results indicate that spontaneous reinnervation of the neo-umbilicus after abdominoplasty together with accurate spatial orientation can occur.

Disclosure of Interest

None to declare

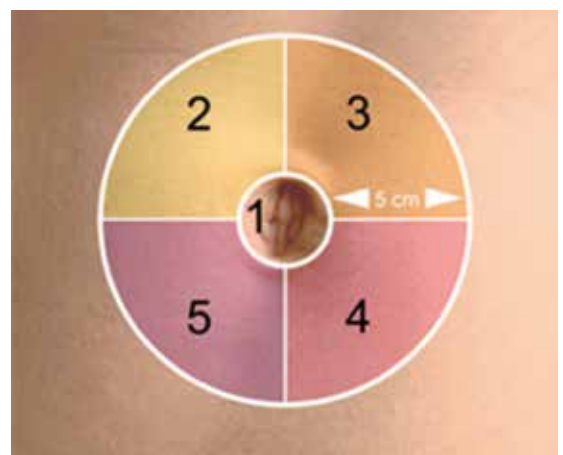


Figure 1

Diagram showing the umbilicus divided into five zones within a circle of 5cm around the center.

Poster abstracts

Id: BTS-8

Topic: Breast surgery

The use of the modified spair mastopexy for severe breast ptosis in massive weight loss patients

Agostino Bruno, Lucio Fasciani,
Casa di Cura Santo Volto - Rome, Italy
Presentation type: Poster

Introduction

Bariatric Surgery leads to severe breast ptosis with medial displacement of the CAM and skin folds in the lateral thoracic wall. The correction is very complex, sometimes leading to disappointing results, mainly due to poor skin conditions. The separate treatment of the skin and breast tissue is therefore necessary to allow lasting results and filling of the upper pole.

Methods

From October 2014 to March 2017, 63 bariatric patients underwent a modified SPAIR mastopexy. An inferior pedicle was designed, centered on the breast meridian, 8cm wide and 8 to 10 cm in length, according to the degree of ptosis. The upper margin of the incision corresponds to the anterior projection of the inframammary fold. The medial and lateral margins are obtained by rotating the breast up and outside and up and medially. The operation begins

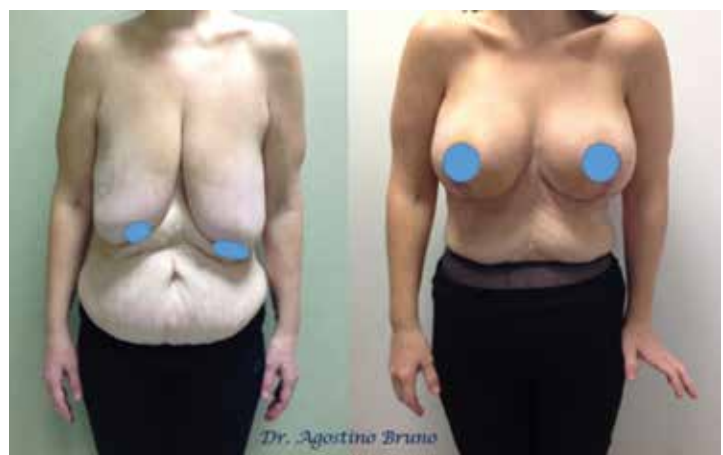with the de-epithelialization and subsequent deepening of the incisions to the muscular plane, obtaining the degloving of the gland. The skin is then redraped around the pedicle, using a J scar and a round-block periareolar suture. The treatment of the lateral thoracic wall was obtained by liposuction in 87% of patients and by surgical removal of the excess skin and fat in 13%, by lengthening the horizontal branch of the J.

Results

The follow-up at 3,6,12,24 months documented the filling of the upper pole, stability of the areolar diameter, absence of bottoming out. The integrated treatment of the lateral thoracic wall has ensured a convex appearance of the breast laterally. There were no major complications.

Conclusions

Breast ptosis in the massive weight loss patients is difficult to treat. The separate treatment of the skin and the breast allows for adequate adaptation of the gland (the filling) to the skin (the container), with stable results.



Poster abstracts

Id: BTS-9

Topic: Buttock augmentation

Enhancing Your Rear is not Rare in China: Creating a curvy Silhouette with New Needle-Hub Buttock Threading

Wen Hsien Ethan Huang
Presentation type: Poster

Background

The purpose of this study was to evaluate the results of gluteal suspension with new needle-hub buttock threading in China.

Methods

Thirty healthy female patients in China between the ages of 40 and 60 (mean, 45 years), who wished to remodel their buttocks from October 2015 to January 2018 were studied retrospectively. All 30 patients were treated with on each buttock using the following procedures: 12(40%) patients were suspended with new needle-hub threading alone; 18(60%) patients were more treated with microfocused ultrasound (Ultherapy) and radiofrequency (Thermage) in the lower back, supragluteal regions, and flanks to improve buttocks contour.

Results

Over a 2-year period, 30 female patients underwent glute-

al suspension procedures. Good aesthetic results without complications were obtained in 27 of 30(90%) cases. Complication occurred in 3 of 30 (10%) patients, including thread removal due to postoperative pain in 1 (3%) patient, and thread protruding due to early heavy exercise in 2 (6%) patients.

Conclusion

The results of this study performed in 30 patients over 2 years in China showed that the suspension with new needle-hub buttock threading performed as a single procedure or in combination with other cosmetic methods helps to enhance and lift ptosed gluteal and paragluteal areas and demonstrates an effective alternative to achieving improved lower gluteal fold contour with very good symmetry and patient satisfaction. The proper selection of patients and the procedures are paramount to achieving a successful outcome.

Key words

Needle-Hub Buttock threading, Gluteal ptosis, Gluteal suspension, Gluteal augmentation, Buttocks.

Poster abstracts

Id: BTS-10

Topic: Facial aesthetic surgery

The Individualized Needle-Hub Threading: Developing a Systemic Approach to High-Risk Facial Rejuvenation

Wen Hsien Ethan Huang

Presentation type: Poster

Background

Thread lift is one of the most popular aesthetic procedures worldwide. Accurate preoperative planning combined with a systemic approach can improve precision and balance in facial rejuvenation techniques.

Complete reviewing of history record and efficient procedure design are critical to optimizing aesthetic outcomes, especially in high-risk conditions. The purpose of this study was to evaluate the efficacy and complication of ten high-risk facial threadings with individualized needle-hub technique in China.

Methods

From November of 2015 to January of 2018, ten high-risk patients between the ages of 35 and 70 (mean, 45 years) in China, who wished to rejuvenate their faces with minimally invasive thread lift procedures were studied retrospectively. Among them, 2 patients are with history of lung cancer, 1 with paroxysmal supraventricular tachycardia (PSVT), 1 with malignant hypertension, 2 with double cancers (thyroid cancer & breast cancer), 1 alcoholism, and 3 with previous poor surgical outcome. Here we describe an individualized needle-hub technique that effectively corrects the aging face, performed under local anesthesia, and with great patient satisfaction.

Results

The results over a mean follow-up period of 18 months were good, with high patient satisfaction. All the complications experienced by the ten patients were minor and temporary including temporal area pain(10%), hematoma(10%), and suture palpability(5%). There were no infection.

Conclusion

The ideal facial threading has the best efficacy, the fewest complications, and ultimately, the highest patient satisfaction. There exists no technique suitable for every patient. Our case study strongly suggests that the Individualized needle-hub threading provides an effective and much safer alternative to current procedures especially for high-risk populations. This report has also shown the need for better studies, and a need for a systemic approach to growing high-risk population for minimally invasive facial rejuvenation.

Key words

Thread lift, Individualized Needle-Hub Threading, High-Risk Facial Rejuvenation.

Id: BTS-11

Topic: Facial aesthetic surgery

Pretarsal augmentation with acellular dermal matrix

Yeo Reum Jeon¹, Ji Hyuk Jung¹, Hyo In Kim¹, Seum Chung¹, Hong Lim Choi²

- 1) Department of Plastic and Reconstructive Surgery, National Health Insurance Service Ilsan Hospital, Goyang, Republic of Korea
- 2) JW Plastic Surgery Clinic, Seoul, Republic of Korea

Presentation type: Poster

Introduction

Conventional lower blepharoplasty emphasizes correction of an aged appearance in lower eyelids by repositioning fat bulges and removing excess skin. However, this technique can create pretarsal flattening, which is associated with senile eyelids and sometimes results in an “operated” appearance following cosmetic plastic surgery^{1,2}. To preserve a natural and youthful appearance after lower blepharoplasty, restoring a narrow and plump pretarsal roll is necessary, especially in patients who have undergone lower eyelid surgery several times before. Furthermore, as slender and chubby pretarsal fullness is considered attractive and youthful in Asian countries, accentuation with makeup, filler injections, or surgical procedures has become widely accepted among young Asian women³⁻⁵.

We describe a simple and long-lasting, pretarsal augmentation technique using acellular dermal matrix (ADM), for use in both younger and older patients with an “operated” appearance.

Methods

Procedures are performed under local anaesthesia. A 5-mm incision is made at the lateral canthus, and a 3-mm incision is made below the lacrimal punctum. A 4-5 mm long × 1-2 mm thick ADM (AlloDerm[®]) graft was prepared. The length of the material depends on canthal length. The

subcutaneous or submuscular plane of the pocket should be tight and the ADM is inserted lateral to medially with a specially designed straight needle. Fixation of the ADM is not necessary and the incision is repaired using 7-0 monofilament suture.

Results

This retrospective chart review evaluated 132 consecutive patients who underwent pretarsal augmentation between 2014 and 2017. All procedures were performed by a single surgeon (HLC). The outcomes and complications were assessed by evaluating preoperative and postoperative digital photographs and medical records. There were no major complications, such as retrobulbar haemorrhage, ectropion, or wound infection. Postoperative haematoma occurred in 1 patient (0.76%) and 3 patients (2.27%) underwent revisional operation. Approximately 97% of the patients were satisfied.

Conclusion

Pretarsal augmentation with ADM is a simple method used to create an attractive pretarsal roll. This technique provides attractive pretarsal fullness for younger patients as well as a natural-looking appearance for patients who have undergone conventional lower blepharoplasty.

Financial disclosure

The authors have no financial interests or commercial associations to declare in relation to the content of this article.

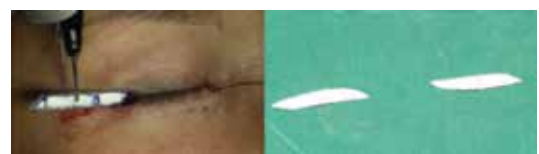

Figure 1.

Operative procedure

References

1. Lewis JM. Augmentation blepharoplasty. *Ann Plast Surg.* 1988;21:434-438.
2. McCollough EG, English JL. Blepharoplasty. Avoiding plastic eyelids. *Arch Otolaryngol Head Neck Surg.* 1988;114:645-648.
3. Chen MC, Ma H, Liao WC. Anthropometry of pretarsal fullness and eyelids in oriental women. *Aesthetic Plast Surg.* 2013;37:617-624.
4. Jeon YR, Rah DK, Lew DH, et al. Pretarsal Augmented Lower Blepharoplasty. *Plast Reconstr Surg.* 2016;138:74-82.
5. Mizuno T. Subciliary augmentation of the lower eyelid in Asians using a deep temporal fascia graft: a preliminary report. *Aesthetic Plast Surg.* 2014;38:303-308.

Poster abstracts

Id: BTS-12

Topic: Lasers

Complex approach to facial rejuvenation with the new laser technology of acoustic interference tissue microtraumatizing and injections of stabilized hyaluronic acid: the data of clinical study

Volkova Natalia, MD, PhD

The Ural State Medical University, Ekaterinburg, Russia

The Laser Cosmetology Clinic "Lineline", Ekaterinburg,

Russia

Presentation type: Poster

Study aim is to evaluate the efficacy of a complex rejuvenation method using laser technology of acoustic interference tissue microtraumatizing (Er: YAG + SMA; 2940 nm) and injections of stabilized hyaluronic acid.

Materials and methods

The study enrolled 60 female patients aged 30-75 years. All patients were divided into two equal groups. The patients of Group I underwent laser rejuvenation procedure. The patients of Group II underwent complex treatment with sequential use of laser rejuvenation and injections of stabilized hyaluronic acid (3 mL in two sessions). Clinical efficacy was assessed in 3 months according to the clinical examination, results of ultrasound skin examination (USE, 22 Hz) and immunohistochemical study.

Results

Clinical examination of patients demonstrated improvement in the skin toning and colour, a significant reduction in wrinkle depth, and a pronounced lifting effect of

the middle and lower third of the face. Among Group II patients, there was a marked increase in skin turgor relative to Group I patients (Picture 1). On 90th days after, the USE showed the 24.21% increasing of dermis density among the Group 1 patients, 36.21% - among the Group 2 patients ($p < 0.05$). The increasing of dermis thickness among Group 1 patients achieved 18.05%, Group 2 patients - 28.53% ($p < 0.05$) (Table 1). The SMAS density increased among Group 1 patients 42.9%, Group 2 - 65.65% ($p < 0.05$). The SMAS thickness increased among Group 1 patients 33.20%, Group 2 - 39.32% (Table 2). The data of immunohistochemical study showed the increasing of collagen type I, collagen type III in the dermis. The changes in collagen fibres among the patients of Group 2 were more marked.

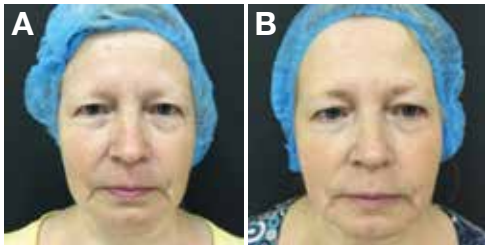
Conclusions

In the Group 2 patients who underwent complex treatment, the results of USE and immunohistochemical study showed more pronounced changes of the dermis and SMAS which confirmed higher clinical efficacy comparing with the Group 1 patients who underwent monotherapy.

Disclosure of interest

No

Poster abstracts

**Picture 1.**

The patient of Group II, 49 y.o. Before (A) and 3 months after (B) the treatment.

Follow-up	Patients of Group I, n=30		Patients of Group II, n=30	
	Dermis density, mkm	Dermis thickness	Dermis density, mkm	Dermis thickness
Before Treatment (mean value \pm standard deviation)	12.39 \pm 4.7	1259.97 \pm 249.88	9.28 \pm 4.15	946.17 \pm 98.86
3 months (mean value \pm standard deviation)	15.39 \pm 4.36	1487.36 \pm 309.19	12.64 \pm 5.06	1216.07 \pm 121.00
Δ initial and in 3 months (%)	24.21	18.05	36.21	28.53

Table 1.

Comparative analysis of the density and thickness of dermis in Groups I and II.

Follow-up	Patients of Group I, n=30		Patients of Group II, n=30	
	SMAS density, mkm	SMAS thickness	SMAS density, mkm	SMAS thickness
Before Treatment (mean value \pm standard deviation)	18.68 \pm 10.41	177.77 \pm 73.65	9.14 \pm 7.15	154.69 \pm 19.13
3 months (mean value \pm standard deviation)	26.69 \pm 8.9	236.79 \pm 69.82	15.14 \pm 8.05	215.52 \pm 18.83
Δ initial and in 3 months (%)	42.9	33.2	65.65	39.32

Table 2.

Comparative analysis of the density and thickness of SMAS in Groups I and II.

Poster abstracts

Id: BTS-13

Topic: Aesthetic Dermatology

Case Report. Positive effect of hybrid stable cooperative complexes of high and low molecular weight HA in Atopic Dermatitis. Two years follow up.

Gabriel Siquier-Dameto, MD
Dameto Clinics International
info@dametoclinics.com
Sloterweg 303A
1171 VC Badhoevedorp
The Netherlands

Background

Atopic dermatitis (AD) is a chronic and relapsing inflammatory skin disease with a typical distribution of pruritic skin lesions that affects up to 20% of children and 3-10% of adults. Traditionally, it was thought that the primary pathogenic mechanism of AD was initiated largely due to immune dysfunction. The mainstay of treatment is therefore topical steroids and systemic immunosuppressant drugs, but both of which can bring long-term toxicity. Hyaluronic acid stable hybrid cooperative complexes could be used as an alternative and preventive therapeutic approach in the management of AD.

Objective

Based on this background, is presented two years follow up of evaluation of the effect of an injectable treatment based on hybrid stable cooperative complexes of high and low molecular weight HA in an adult patient affected by AD.

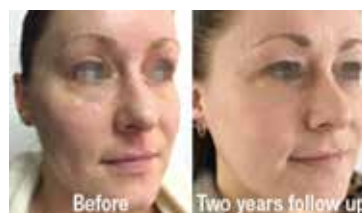Materials and methods

Were performed 3 treatment sessions as described in the product leaflet, 2mL per session were used with the Bio

Aesthetic Points technique, sessions were programmed once a month, maintenance sessions were done every 2 months.

Results

The treatment produced a continuous, gradual therapeutic effect with significant improvements and was effective in attenuating inflammation and maintaining the skin barrier in AD. No serious side effects were observed, with the exception of a single bruising, which healed without complications within 48 hours.



Conclusions

These preliminary results could imply that Hyaluronic Acid stable hybrid cooperative complexes could be used as a complementary approach in the management of AD.

Disclosure of interest

GS has received advisory/speaker honoraria and/or research funding from IBSA.

Id: BTS-14

Topic: Aesthetic Dermatology

Case Report. Neck rejuvenation multimodal approach with botulinum toxin and Hyaluronic Acid stable hybrid cooperative complexes.

Gabriel Siquier-Dameto, MD
 Dameto Clinics International
 info@dametoclinics.com
 Sloteweg 303A
 1171 VC Badhoevedorp
 The Netherlands

Background

Combination treatment with toxins and hyaluronic acid is the standard regimen in facial rejuvenation. However a multimodal approach is essential for neck rejuvenation because many factors contribute to the aging of the neck.

Objectives

Based on this background, has been evaluated safety and effectiveness and compared combination treatment with botulinum toxin type A and a 32mg/mL Hyaluronic Acid stable hybrid cooperative complexes of high and low molecular weight for neck rejuvenation in female subjects.

Methods

Subjects were treated with two kinds of interventions in a first session, as follows: (A) 2mL of Hyaluronic Acid stable hybrid cooperative complexes of high and low molecular weight for restoring skin laxity were used with the Bio Aesthetic Points technique; and (B) botulinum toxin type A injection for platysmal bands.

Subjects were treated in a second session one month

after the first one with 2mL of Hyaluronic Acid stable hybrid cooperative complexes of high and low molecular weight for restoring skin laxity with the same technique.

Results

All subjects showed a continuous, gradual effect with significant clinical improvement of neck aging after combined treatment. Subjects treated with combination therapy had greater improvement from baseline than subjects treated with botulinum toxin type A or the Hyaluronic Acid stable hybrid cooperative complexes of high and low molecular weight alone.

Conclusion

Based on these preliminary results, botulinum toxin type A and Hyaluronic Acid stable hybrid cooperative complexes of high and low molecular weight treatments are effective and safe when either alone or in combination to rejuvenate the neck. Combination therapy is superior to either modality used alone.

Disclosure of interest

GS has received advisory/speaker honoraria and/or research funding from IBSA.

Poster abstracts

Id: BTS-15

Topic: Breast surgery

Title: Reoperation Rates Using Natrelle® 410 Anatomical Implants in Primary Breast Augmentation: an International, Multicenter, Retrospective Study

Isabel de Benito, MD, DDS1; Rony Moscona, MD2; Armand Azencot, MD3; Till Scholz, MD4; Paul E. Banwell, MB, BS5; Graeme Kerson, BSc6; Michael B. Silberberg, MD, MBA6

- 1) Porcuna & de Benito, Madrid, Spain
- 2) Moscona Clinics, Israel
- 3) Cabinet de Chirurgie Esthétique du Grand Théâtre, Bordeaux, France
- 4) Department for Plastic and Aesthetic Surgery, Florence-Nightingale Hospital, Düsseldorf, Germany
- 5) The Banwell Clinic, McIndoe Centre, East Grinstead, UK
- 6) Allergan Ltd, Parkway, Marlow, Bucks, UK

Presentation type: Poster

Introduction/Background

Breast augmentation is a common surgical procedure that comes with associated risks. Some patients will experience complications or require reoperation.

Objectives/Methods

The objective of this international, multicenter, noninterventional, single-arm, retrospective study was to evaluate the incidence and etiology of reoperations among patients who had undergone a primary breast augmentation for aesthetic purposes with Natrelle® 410 cohesive BIOCELL™ textured anatomical implants. The study was based on a review of medical records and patient-completed questionnaires. All subjects were aged 18 years or older and had been implanted via an inframammary fold incision. Follow-up ranged from 3 to 10 years.

Results

Analyses were performed on 175 patients in the per-protocol population (baseline mean age: 35.7 ± 10.6 years); median follow-up time was 5.9 years. The median size implant used was 320 g (range: 125–620 g). The majority had submuscular/dual plane implant placement (n=164, 93.7%). At the time of follow-up, 28 patients (16.0%) had undergone

reoperation, of whom 25 had undergone implant removal. The most frequently observed adverse events were capsular contracture (n=11; 6.3%), device dislocation (n=10; 5.7%), and device breakage (n=8; 4.6%). Implant removal occurred in 8 patients with capsular contracture, 7 patients with device dislocation, and 6 patients with device breakage; some patients experienced more than one such event. Reoperations occurring after database lock will be discussed. Double capsules were observed in 4 patients (2.3%), but recorded as an adverse event in 2 patients (1.0%). There were no cases of breast-implant associated anaplastic large cell lymphoma.

Conclusions

The results support the medium to long-term safety of Natrelle® 410 implants when used in aesthetic breast augmentation in a real-world setting, with reoperation rates and reasons for implant removal that align with previous data.

Disclosure of Interest

Graeme Kerson and Michael Silberberg are employees of Allergan. Isabel de Benito has been a consultant for Allergan and has received payment from Allergan for personal fees related to this study and for other activities. Till Scholz has been a consultant for Allergan. Rony Moscona, Armand Azencot, and Paul Banwell have nothing to disclose.