Complete Edentulism Treated with Flapless Computer Guided Implant Placement and Same Day Denture Conversion to Screw Retained Temporary Acrylic Hybrid Restoration

One of the most beneficial services available to the edentulous patient is the placement of enough implants to be able to have a completely implant supported prosthesis. The effectiveness and predictability of this type of prosthesis is well established in the literature and in practice throughout the world. In order to make the transition to a fixed prosthesis more convenient, same day conversion to a fixed temporary restoration can be utilized. This additionally avoids the potential damage of wearing a mobile removable full denture over the healing implants and the need for a second full arch surgery to uncover the integrated implants 4 to 6 months after placement. By placing 6 to 8 implants equally spaced around the edentulous arch, all of which have measurably good to excellent primary stability and by having the patient maintain a soft diet through the critical first 2 months of bone healing, the cross arch stability achieved with a temporary fixed prosthesis will be adequate to allow integration of the implants even under immediate loading.

With cone beam computed tomography (CBCT) and third party 3D software it is possible to perform flapless computer guided implant placement which offers many advantages including less bleeding, more predictability, less post op discomfort, shorter surgery time and shorter healing time. Once the surgeon has done several computer guided placements utilizing flaps with high quality computer designed and generated guides, he/she will quickly understand that the accuracy of this computer guided approach overcomes the perception of this being a blind procedure. The surgeon visualizes the patient's anatomy and proposed prosthetics in advance using third party software from 3D Diagnostix Inc. (3DDX) and places the implants virtually using the software. The surgical guide fabricated from this virtual plan by 3DDX will predictably put the implant in the exact location as designed in the software and, in this sense; it is not a blind procedure. This type of planning and surgery makes the overall treatment more predictable with implants placed in the most ideal prosthetic positions possible consistent with adequate boney support for the healing implants.

Case Study

A 62 year old Hispanic male presents to Implant Educators for treatment of complete edentulism with implants in hopes of having a fixed prosthesis that eliminates palatal coverage. His medical history is significant for mild hypertension, hypothyroidism, high cholesterol and gout well controlled with amlodipine, levothyroxine, simvastatin, and allopurinol respectively. His also reports taking a prophylactic dose of 81 mg aspirin daily and denies history of any cardiovascular events.

His existing denture is well fitting with a good smile line and occlusal plane. These are important factors to consider when planning the conversion of an existing denture to an immediate fixed temporary. Not only will the temporary fixed hybrid be maintained in the same position as presented preoperatively in the denture, but the tissue surface of the existing denture will be duplicated in the fabrication of the guide by 3DDX; hence the fit of the guide is dependent on the fit of the existing denture. If the existing denture is inadequate pre-operatively, the starting point is to fabricate a well fitted, well designed denture.

Fig. 1: Smile Photo evaluation.

The attached gingiva was found to be adequate for the flapless protocol. Generally, a minimum of 2 mm of attached gingiva labial to site of the punch is recommended in order to avoid mucogingival complications.

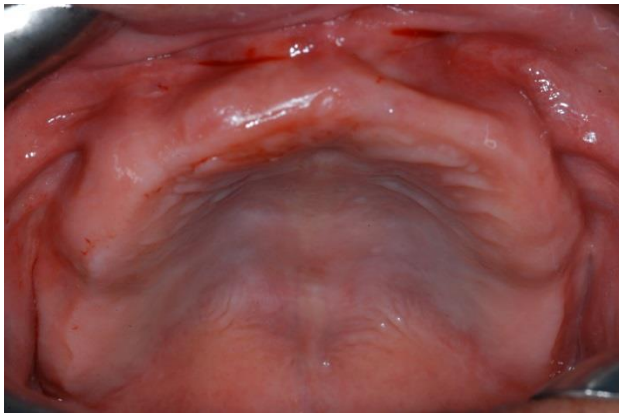

Fig. 2: Edentulous ridge evaluation.

A CBCT scan of the patient wearing his existing denture with fiducial radiographic markers placed on the denture was obtained. A second CBCT scan of the denture alone allows the merging of the denture to the patient's CBCT using the fiducial markers as alignment positioners.

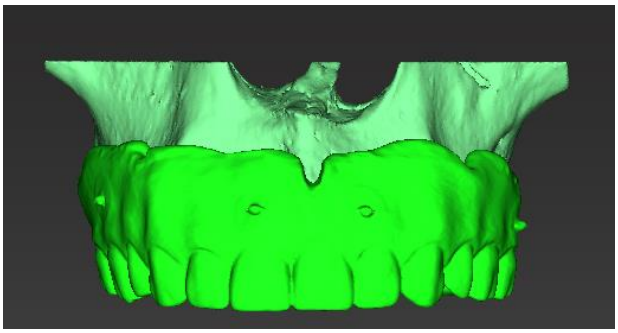

Fig. 3: Merging of the Patient CBCT with the Denture CBCT.

The implants were planned as parallel as possible with a minimum of 2.0 mm of surrounding bone and the prosthetic projections lingual to the facial aspects of the denture teeth.

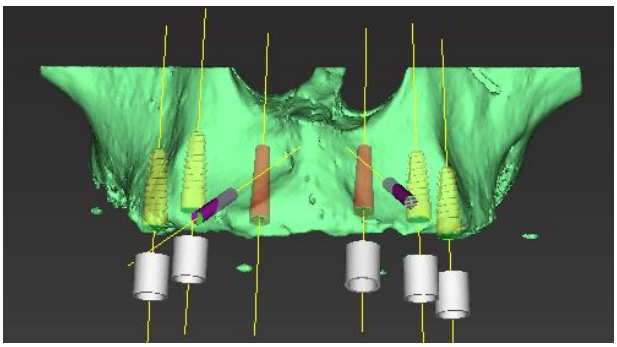

Fig. 4a) Implant planning relative to existing bone

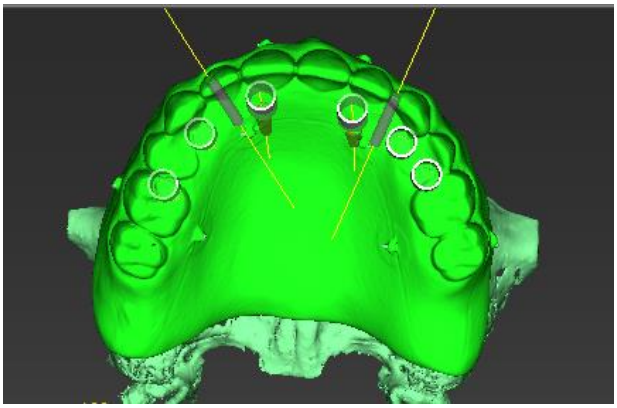

Fig.4b) Planned implant positions for projected prosthesis

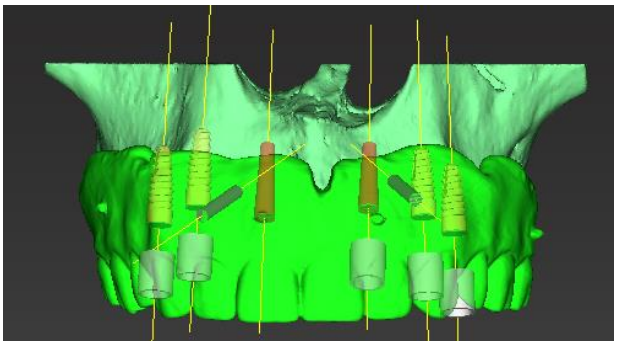

Fig. 4c) Parallel positions of planned implants

The soft tissue (red) was evaluated during the planning. A soft tissue impingement was discovered digitally and the surgical protocol was modified to accommodate this.

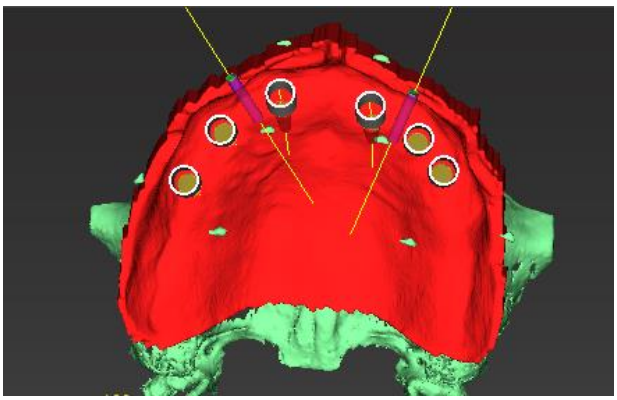
a)

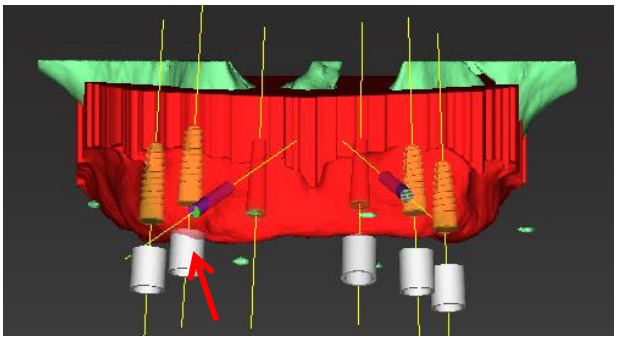
b)

Fig. 5: The soft tissue evaluation within the virtual plan from the occlusal view a), and from the anterior view b). Note the slight soft tissue impingement by the guide sleeve highlighted by the red arrow in b).

The surgery was carried out using a flapless protocol. The guide was evaluated and the fit verified prior to beginning the osteotomies. There was a slight impingement of tissue by two of the guide tubes so the guide was positioned and held firmly in place by a single finger in the palatal vault of the guide and the initial tissue punch for the two corresponding implants were used through the guide. The guide was removed and the next larger tissue punch was used freehand by centering the punch around the initial punch circumferentially and making a larger opening that would accommodate the guide sleeve. After the tissue impingements were removed in this way, the guide was repositioned and the remaining punches and osteotomies proceeded according to guided protocol.

Fig. 6: Surgical guide in place prior to beginning of the osteotomies

Fig. 7: Guide in place with fixation screws. The guide was also held in the posterior with finger pressure during all drilling as the guide will tend to tip downward in the posterior even with secured anterior fixation pins in place.

All implants were placed using the BioHorizons fully guided kit for implant placement. With this protocol, all drilling is done through drill sleeves designed within the guide by the 3DDX software to control the angulation and the depth of the drill. A BioHorizons drill sleeve is positioned within the guide at each implant site that is unique to the diameter of implant that is being placed. The vertical position and angulation of the sleeve is coordinated with the drill length to control the drilling of the osteotomy so that the implant is placed in the bone in the same positon as designed in the 3D plan. The BioHorizons guided kit has a precision fitted key for each sequential drill diameter used to create the osteotomy. The key is inserted into the sleeve in the guide. This sleeve/key combination directs each drill to proper angle and depth positions. Finally, the implant is placed through the guide. This avoids implant migration during placement, a common complication with non-guided surgery. After integration, the guide can be used with the same tissue punches to uncover the implant by making a precisely drilled opening in the tissue around the implant. Once again, no flap is required.

Fig. 8: Tissue punches are used to open the sites for flapless access. This same punch can be used to uncover the implant after integration.

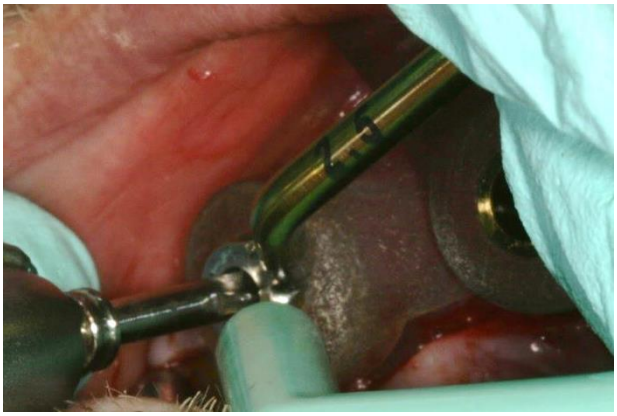

Fig. 9: The Drill Key is placed into the sleeve in the guide and the drilling is accomplished through the key. There is a separate key for each drill diameter. Each sequential key fits into the guide sleeve and accommodates the sequentially larger drill sizes to create the final osteotomy. Shown here is the 2.5 mm drill diameter being inserted into the key which is in position in the guide.

Fig. 10: The drill is at full depth of the design when the drill stop touches the top of the key as shown here.

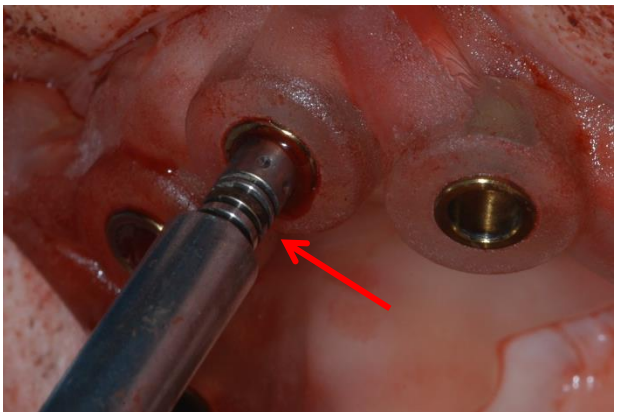

Fig. 11: The implant driver precisely fits the guide sleeve so the implant can be placed through the guide thus avoiding migration of the implant during placement. A stop key (not inserted yet in this photo) fits into one of 4 slots (arrow) on the implant driver for depth control during implant placement. The implant is at the proper depth when the stop key inserted in the proper slot touches the top of the guide sleeve.

Initial stability of all implants was confirmed using Resonance Frequency Analysis (Osstell). All implants had an Osstell ISQ between 60 to 78.

The denture was taken to the lab and prepared by the lab technician. By placing the guide over the stereolythic model produced by 3DDX and marking the implant positions, the openings in the denture to accommodate the temporary abutments could be made visually.

Fig. 12: Denture preparation for attachment to the implant temporary abutments.

The temporary abutments were placed in the mouth and the denture returned from the lab with the holes predrilled to accommodate the temporary abutments. Very slight additional enlargement of the holes was performed to make certain the denture had no contact with the protruding temporary abutments. The denture is seated over the temporary abutments, oriented and held firmly in place by pressing into the palatal vault of the denture, thus assuring the proper orientation of the denture to the hard palate and soft tissues while it is attached to the temporary cylinders using light cured resin. After the newly converted denture is finished and polished in the lab, it is placed in the mouth and screw retained to the implants. The occlusion is adjusted and the patient leaves with an implant supported temporary. The patient is advised to use a soft diet during the first two months of the bone remodeling process. The temporary restoration will be converted to a full arch milled zirconia Prettau screw retained prosthesis after 4 - 6 months of osseointegrartion.

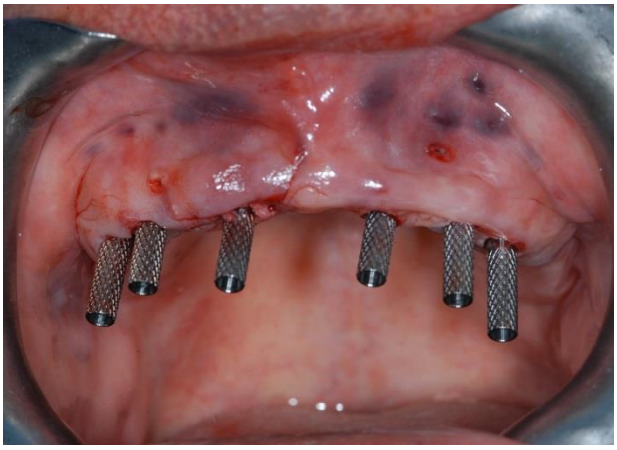

Fig. 13: All 6 implants placed according to the plan with temporary abutments in place that will be attached to the denture to create a fixed hybrid temporary restoration.

Fig. 14: Attachment of the denture intraorally to the temporary abutments using light cured resin. Note the accuracy maintained from the plan through placement and then conversion.

Fig. 15: The denture conversion is started in the lab by placing analogs, removing most of the labial flange and creating a soft tissue model to work with during the conversion.

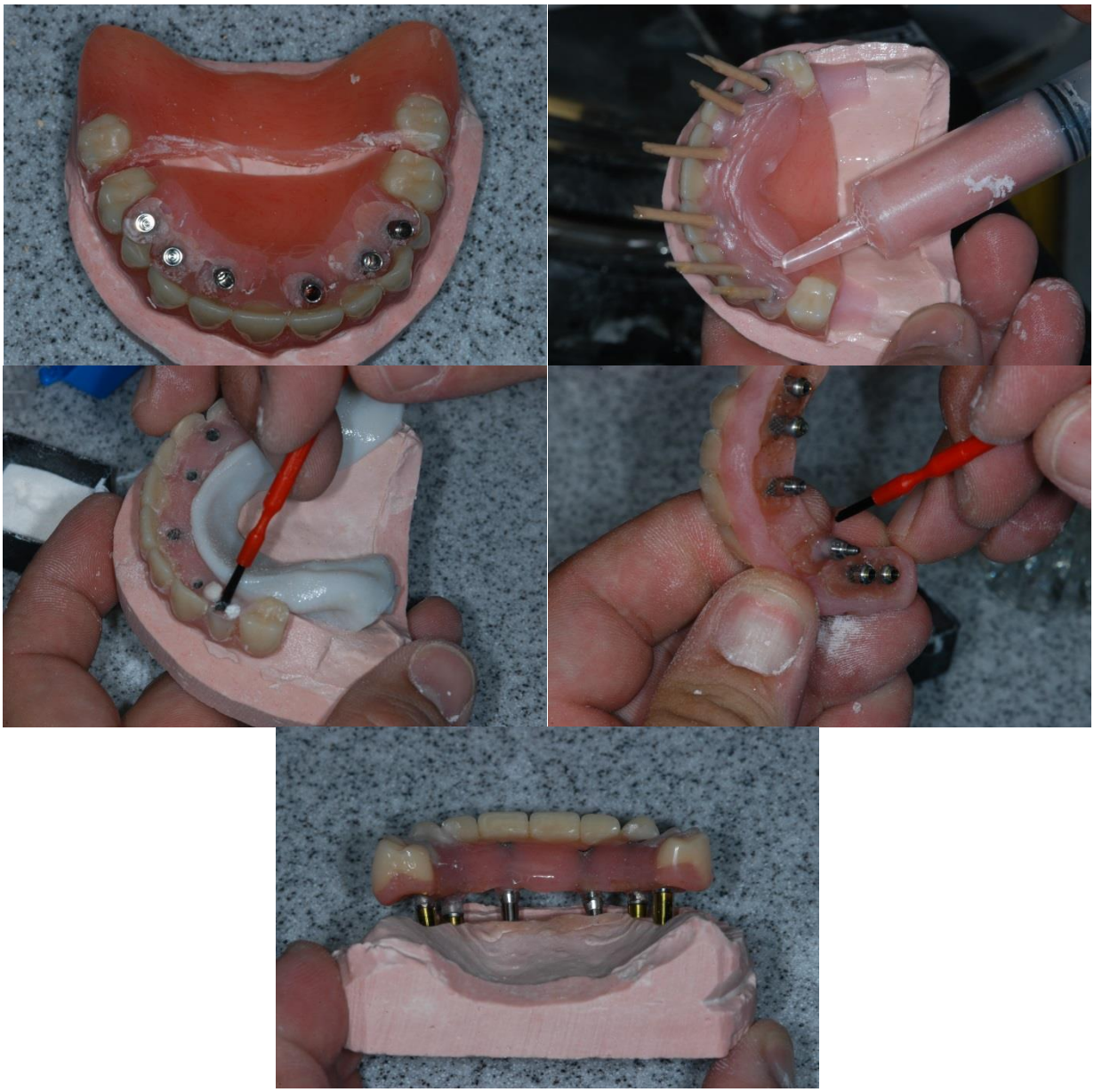

Fig. 16: The denture conversion continues by removing more of the flanges and the palate of the denture, then shortening the temporary abutments to just below the occlusal plane and using cold cure acrylic to create the finished screw retained fixed hybrid temporary. The emergence profiles for each of the implants are refined with a small brush and powder liquid addition technique.

Fig. 17: The finished screw retained fixed hybrid

Dr. Pate maintains a private practice in Auburndale, FL where he has practiced for the past 27 years. Dr. Pate is also an adjunct faculty for University of Florida and teaches clinical and implant dentistry at the University of Florida Residency in Advanced Dentistry at the University of Florida Dental Clinic on the St. Petersburg College Campus in Seminole, Florida. He is a diplomat in the International College of Oral Implantologists (ICOI). Dr. Pate is the clinical director for Implant Educators, a 7 month, University of Florida based continuum in implant dentistry where dentists learn about all aspects of surgical implant dentistry in explicit detail from extraction and socket grafting to implant placement, sinus grafting and more advanced bone grafting as well as all aspects and types of implant restoration. The unique aspect of this course that is not replicated with any course anywhere is the opportunity for the students to actually perform the surgeries under the direction and supervision of the instructors. The students in the course placed the implants and performed the conversion presented in the previous case study under the direct supervision of Implant Educators Co-Director, Dr. Arthur Acker. Dr. Acker is a Diplomate of the ICOI, MAGD Academy of General Dentistry and Adjunct Professor at the University of Florida, College of Dentistry. He has a full time private practice in Venice, FL. He has taught clinical dentistry for more than 30 years. For more information about Implant Educators go to www.implanteducators.com

3D Diagnostix started in 2005 out of current HQ in Boston, Massachusetts as one of the first Guided Surgery service providers. Since then, 3DDX has expanded to provide turn-key Guided Surgery solutions such as Implant Treatment Planning, Surgical Guides, Radiology Reports and Implant Planning Software to dental professionals all over the world.

For more information about 3DDX services and surgical guide visit: http://www.3ddx.com