

**Patient Name:** \_\_\_\_\_ **DOB:** \_\_\_\_\_ **Date:** \_\_\_\_\_  
**Gender:** \_\_\_\_\_

**Scan Center:** \_\_\_\_\_ **Date of Scan:** \_\_\_\_\_  
**Referring Doctor:** \_\_\_\_\_

---

**Images provided:** Cone Beam CT images in the bone window. Axial, coronal and sagittal planes.

**Clinical Info:**

**Relevant History:** Implants planned

**Client Notes:**

**Findings:**


**Mandible:** findings on 34 and 35 are consistent with the history of endodontic surgery, the bone is completely healed and no pathology noted. No radiographically remarkable dental abnormalities detected in other segments of the mandible as well.

**Impressions and recommendations:**

No active pathology detected

**Radiologist name and signature:**

Thank you for the referral of this patient and the opportunity to serve your practice.

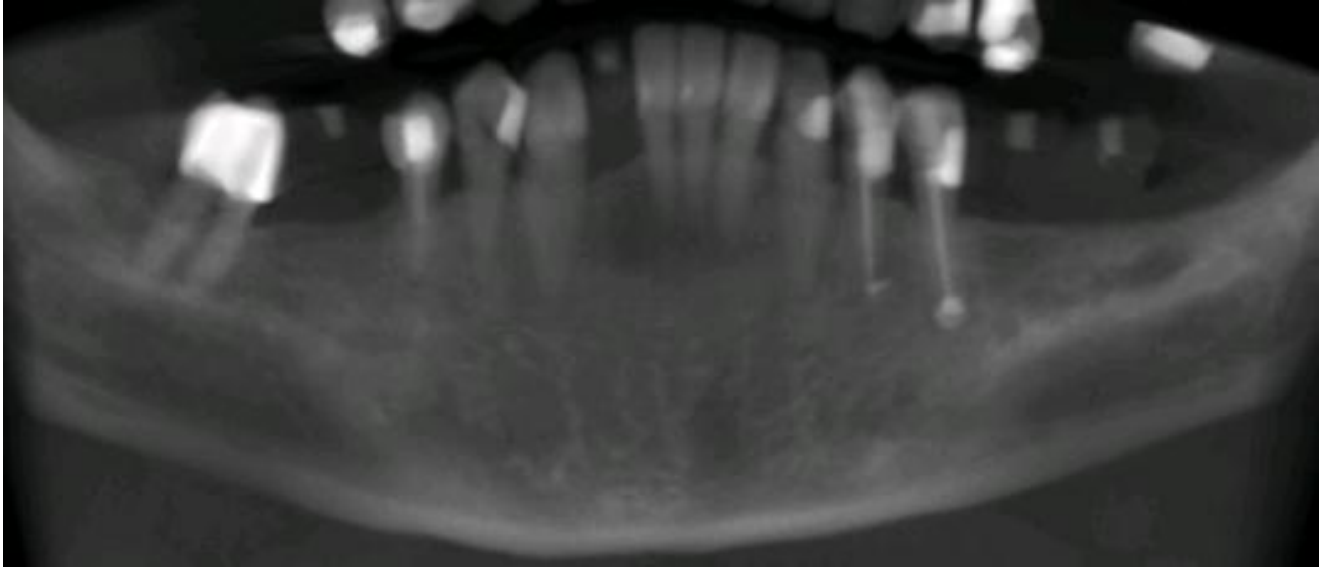


---

Marcel Noujeim DDS MS

Diplomate, American Board of Oral & Maxillofacial Radiology

*Cone Beam CT images are suboptimal for the visualization of soft tissue and fine bone detail.*



Panoramic reconstruction