

**Patient Name:** \_\_\_\_\_ **DOB:** \_\_\_\_\_ **Date:** \_\_\_\_\_  
**Scan Center:** \_\_\_\_\_ **Gender:** \_\_\_\_\_  
**Referring Doctor:** \_\_\_\_\_ **Date of Scan:** \_\_\_\_\_

---

**Images provided:** Cone Beam CT images in the bone window. Axial, coronal and sagittal planes.

**Clinical Info:**

**Relevant History:** Implants planned

**Client Notes:**

**Findings:**

**Maxilla:** moderate to severe periodontal bone loss on 23, 25 and 26

**Sinuses:** mild to moderate mucosal thickening in the left sinus


**Impressions and recommendations:**

Periodontal evaluation needed to assess the prognosis of 23, 25 and 26

Mild to moderate sinusitis in the left sinus, no additional assessment needed in absence of clinical signs and symptoms

**Radiologist name and signature:**

Thank you for the referral of this patient and the opportunity to serve your practice.

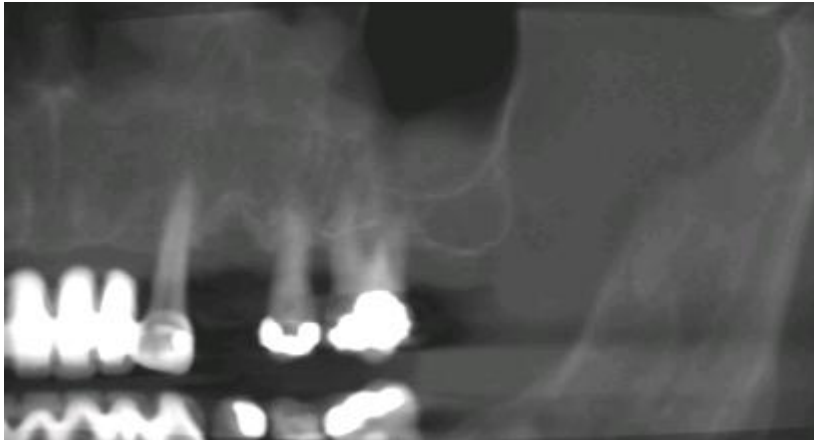


---

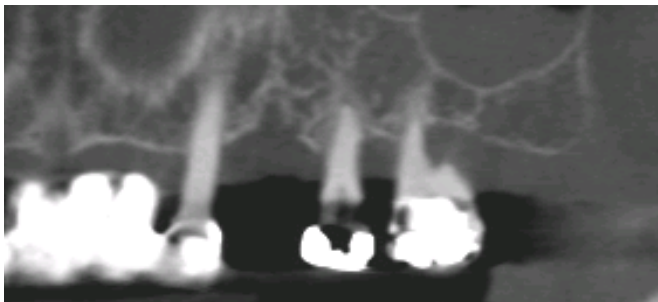
Marcel Noujeim DDS MS

Diplomate, American Board of Oral & Maxillofacial Radiology

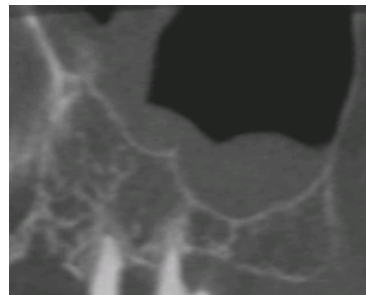
***Cone Beam CT images are suboptimal for the visualization of soft tissue and fine bone detail.***



Panoramic reconstruction



Periodontal bone loss



left sinus