



Date: 12-23-08

Patient Name:

DOB: 12-27-1934

Gender: female

Scanning Center:

Referring Doctor:

Date of Scan: 11-20-2008

Images provided: Cone Beam CT images in the bone window. Axial, coronal and sagittal planes. FOV:

Clinical Info: Implant analysis requested.

Relevant History: Severe resorption to maxillary bone.

Client Notes: Please rule any pathology out. Evaluate existing bone width and height in maxilla for a possible complete denture supported by implants.

Diagnostic Objectives:

1. Implant Planned
2. Sinus Evaluation
3. Rule Out Pathology

Findings:

Maxilla: Multiple periapical low density areas were noted, especially on the left side

Mandible: 1) a prominent low density area was noted in the symphysis area of the mandible. 2) A well circumscribed low density area was noted around the apex of the mandibular left 2nd molar. 3) A small localized area of increased density was noted at the alveolar crest in the left 3rd molar region.

TMJs: A lack of symmetry was noted; the articular fossae are symmetrical but flattened in appearance; the right condylar head exhibits sclerosis and lacunae formation; the left condylar head exhibits some sclerosis. Both condylar heads exhibit flattening of the anterior-superior surfaces.

Sinuses: 1) an increased density and thickening of the lining of the left maxillary sinus was noted apical to teeth with low density areas; the low density apical to the maxillary left 1st molar appears to perforate into the sinus. 2) There is an increase in thickness of the lining of the sphenoid sinus.

Other findings: 1) a metallic, long narrow foreign body is noted in the symphysis of the mandible. 2) There is evidence of spinal surgery.

Patient Name:

DOB: 12-27-1934

Gender: female

Recommendations:

Periapical low density areas are consistent with periapical inflammatory disease of pulpal origin; clinical evaluation is suggested. The area of increased density noted in the mandibular left 3rd molar region is consistent with a residual root/bone fragment.


TMJ: The changes noted within the TMJ's are consistent with moderate degenerative joint disease; correlation of the radiographic appearance with patient's clinical findings and symptoms is suggested.

Maxillary and Sphenoid sinus: the findings are consistent with chronic mucositis of odontogenic origin in the maxillary sinus; the sphenoid could be associated with chronic allergy or an independent mucositis; review of patient history for chronic headache; physician referral if indicated by clinical findings and medical history.

Metallic foreign bodies; review of past medical and surgical history is suggested.

Radiologist name and signature:

Thank you for the referral of this patient and the opportunity to serve your practice.



John W. Preece DDS, MS

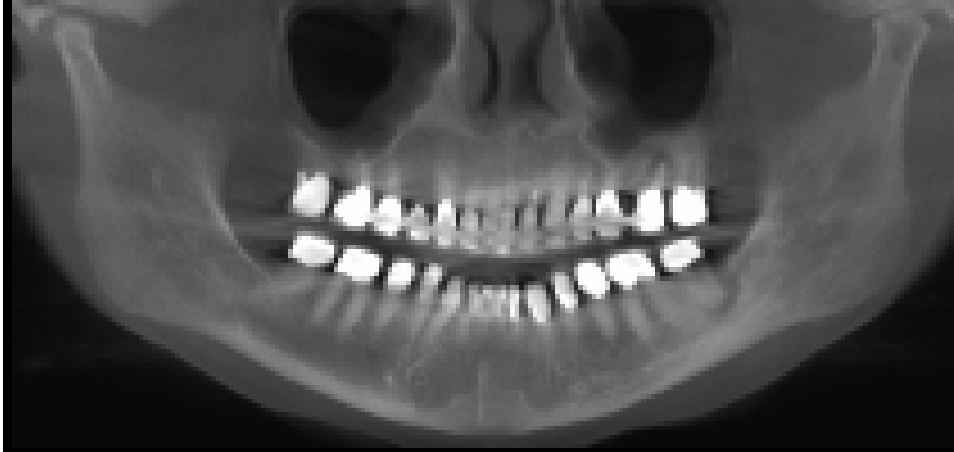
Diplomate, American Board of Oral and Maxillofacial Radiology

Patient Name:

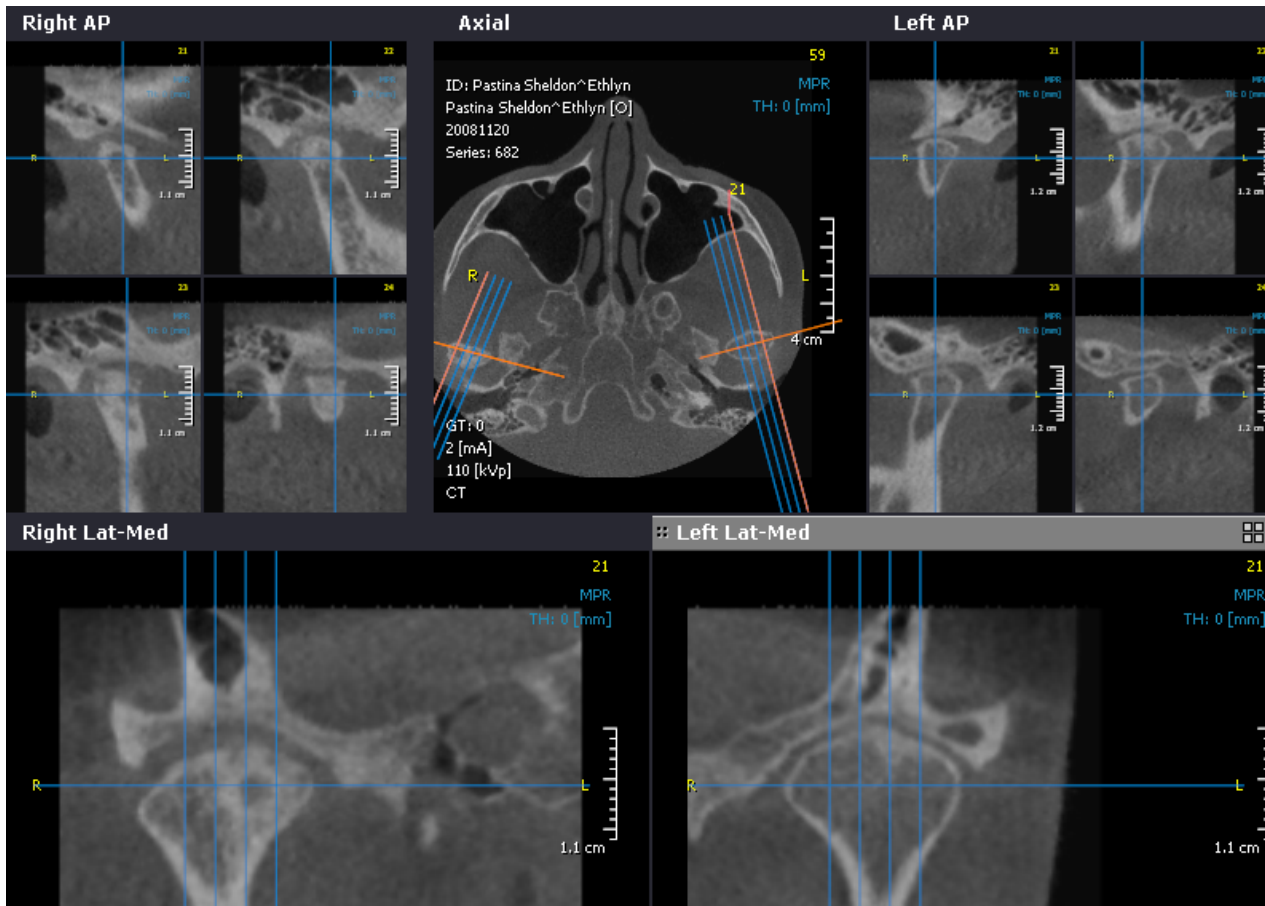
DOB: 12-27-1934

Gender: female

Cone Beam CT images are suboptimal for the visualization of soft tissue and fine bone detail.



Reconstructed panoramic radiograph

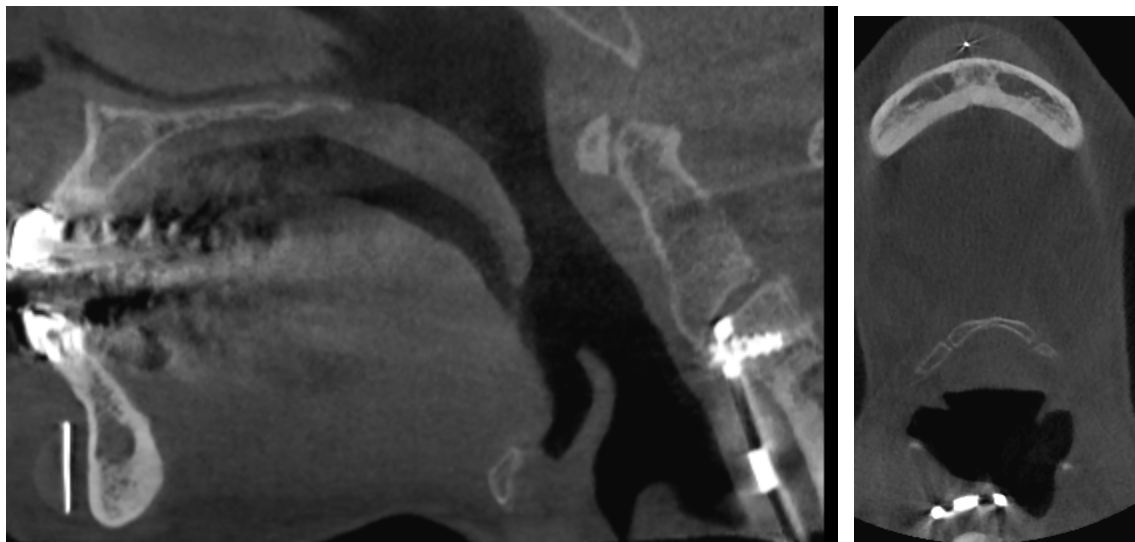


Right and left TMJ; note remodeling of articular fossa; sclerosis and lacunae formation within the right condylar head; sections are 3 mm apart; the lower right section is the more medial section

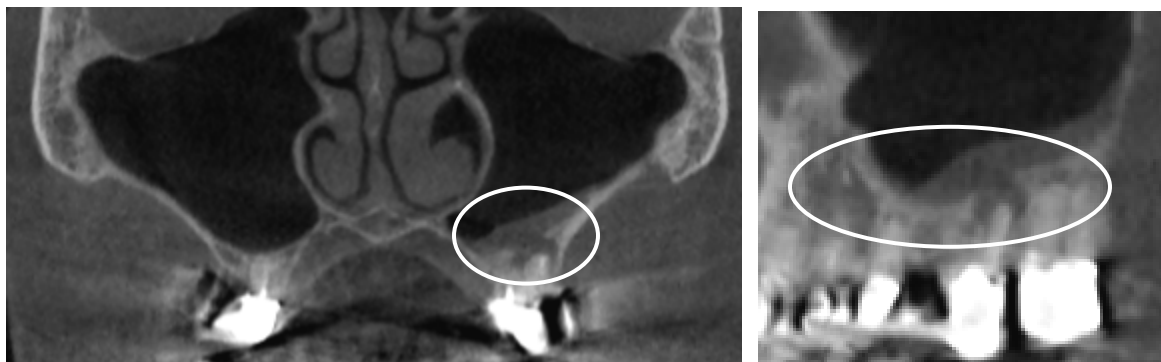
Patient Name:

DOB: 12-27-1934

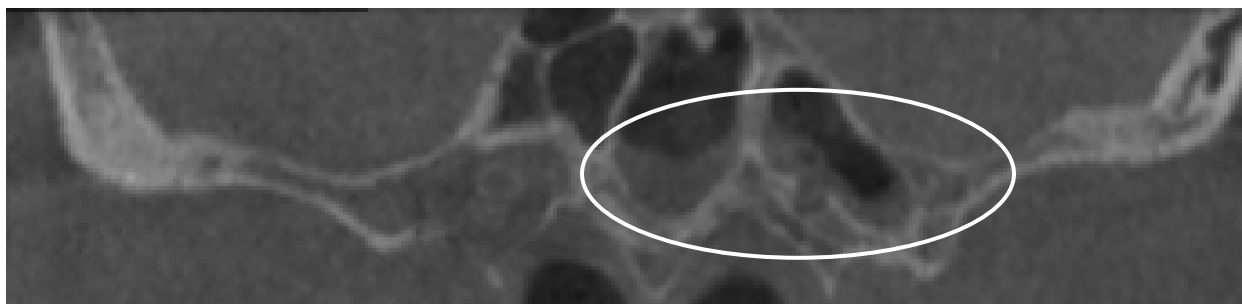Gender: female



High density metallic objects mandibular symphysis and spine



Increased density and thickening of the lining of the left maxillary sinus apical to multiple teeth with periapical low density areas; the area apical to the maxillary left 1st molar appears to perforate into the sinus.

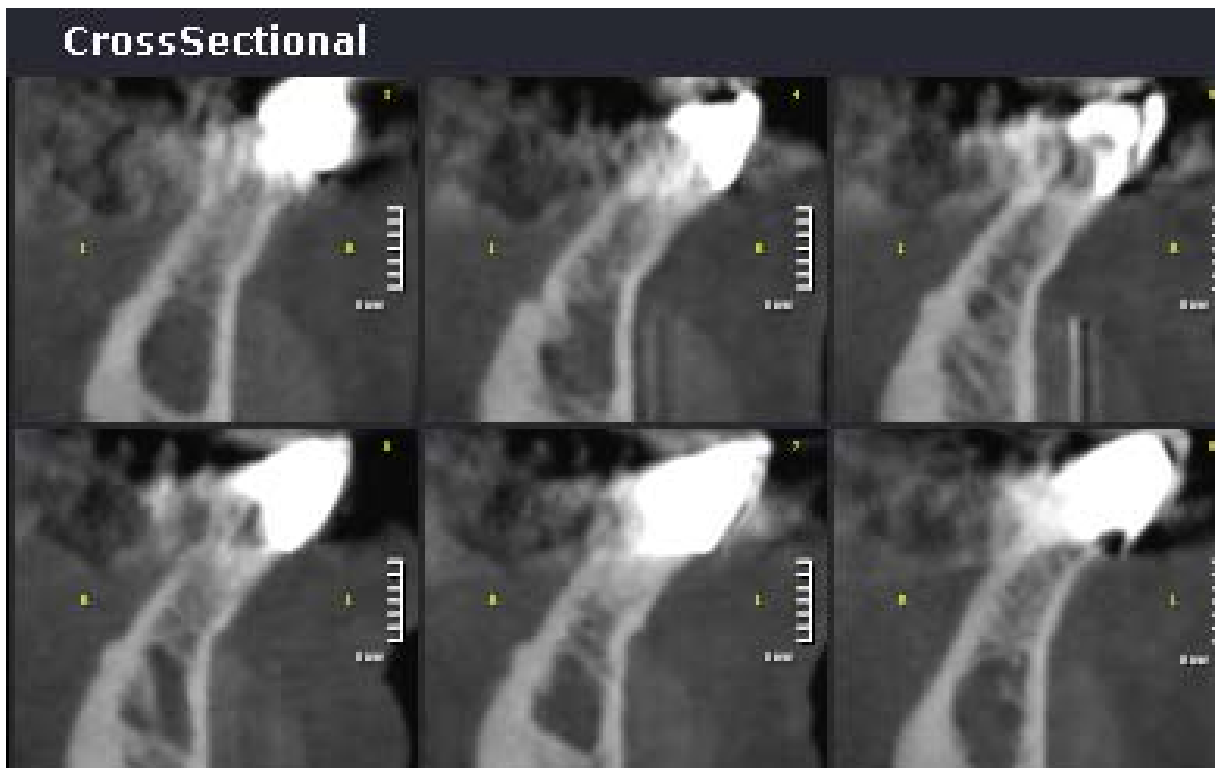
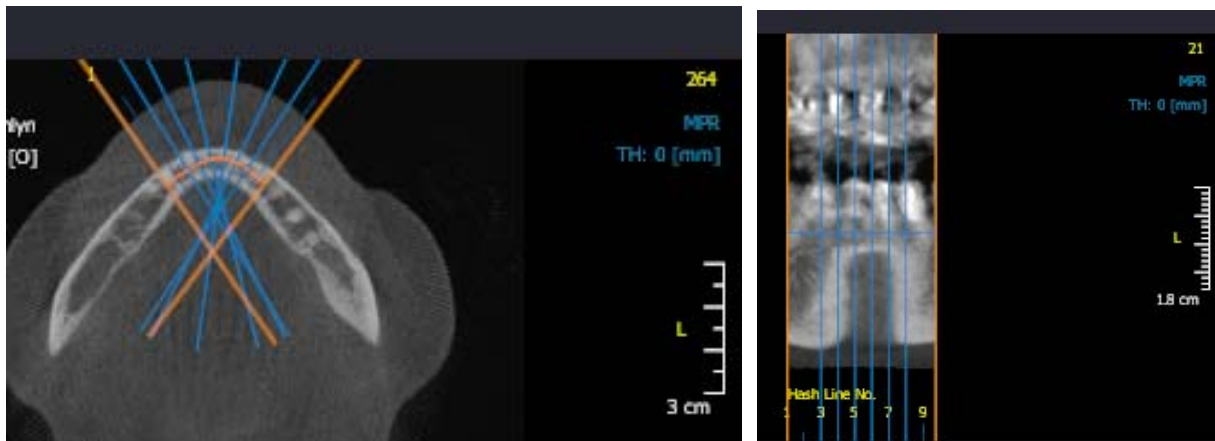


Area of increased density noted within the sphenoid sinus

Patient Name:

DOB: 12-27-1934

Gender: female

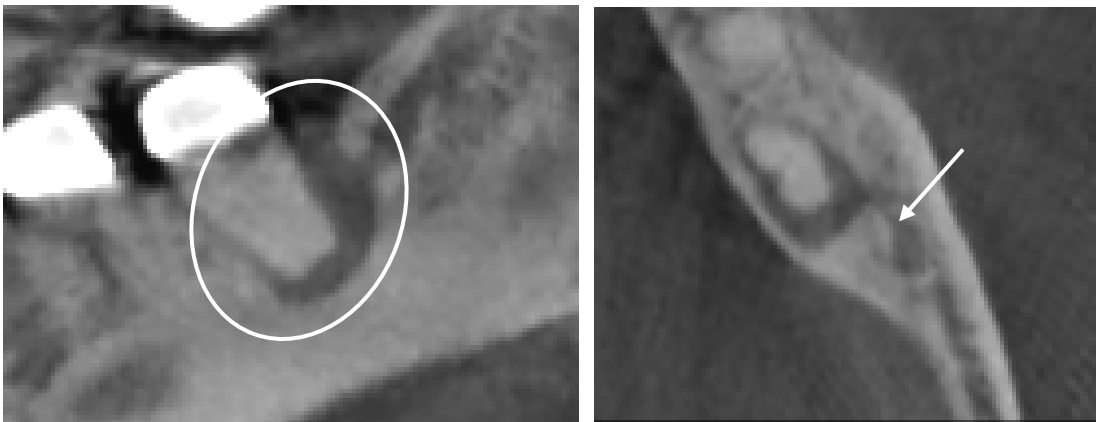


Low density area noted within the anterior mandible

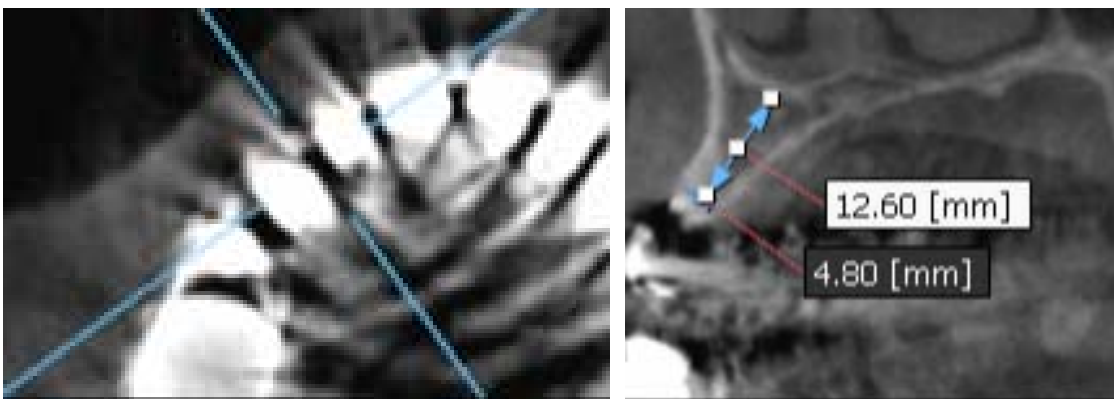
Patient Name:

DOB: 12-27-1934

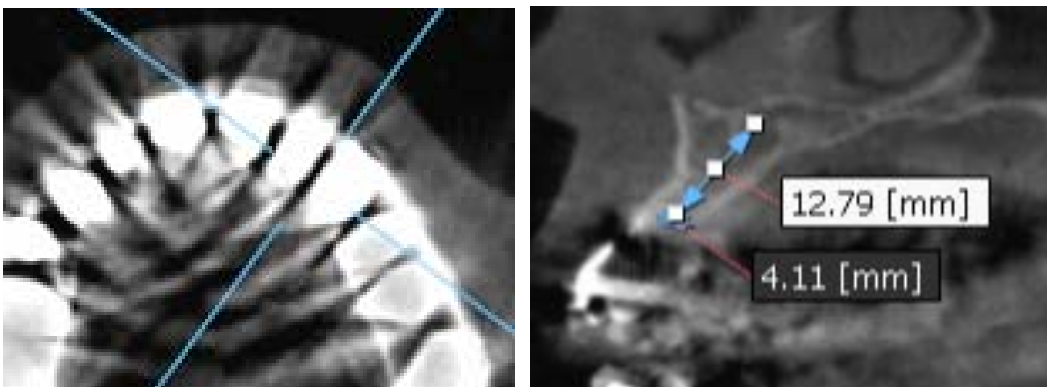
Gender: female



Periapical low density area, apex of the mandibular left 2nd molar; just distal may be seen an area of increased density with a surrounding low density line suggesting a retained root/bone fragment in the 3rd molar region [arrow]



Sample cross-section through the alveolar crest between the right maxillary lateral and canine


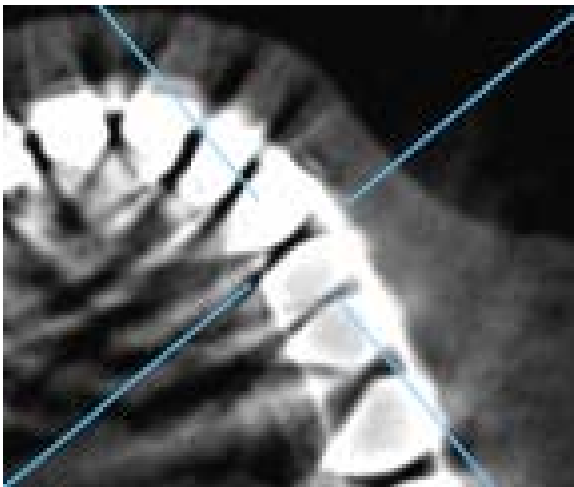


Sample cross-section through the alveolar crest between the left maxillary lateral and canine

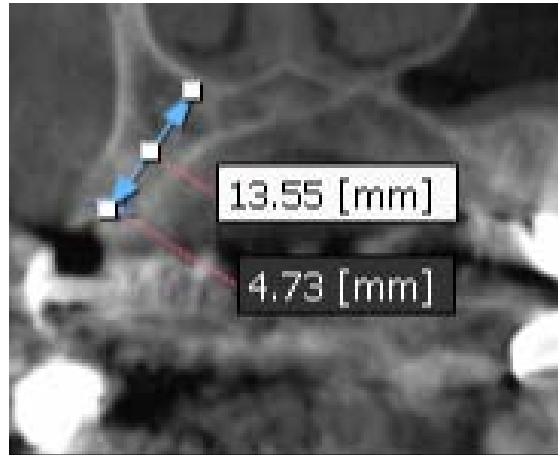
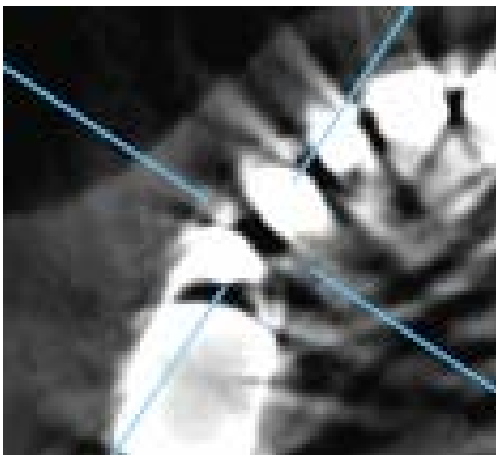
Patient Name:

DOB: 12-27-1934

Gender: female



Selected cross-section through the alveolar process between the maxillary left canine and 1st premolar



Selected cross-section through the alveolar process between the maxillary right canine and 1st premolar

Phone: 617-820-5279
Email: Info@3ddx.com
Web: www.3ddx.com
www.conebeam.com

3D Diagnostix Inc.
167 Corey Rd. Suite #111
Brighton, MA
02135