Pressure Injury Pocket Guide

Convatec is committed to supporting the **National Pressure Injury Advisory Panel** (NPIAP) in their quest to increase awareness about pressure injury prevention and to educate the public on this topic.

As such, we have launched **#TimeisPressure** as a means of providing resources to help raise awareness of pressure injuries and aid their prevention.

Follow our pocket guide for pressure injury classification and areas at risk.

What is. . .

Pressure Injury[1]

A pressure injury is localized damage to the skin and underlying soft tissue usually over a bony prominence or related to a medical or other device.

The injury can present as intact skin or an open ulcer and may be painful. The injury occurs as a result of intense and/or prolonged pressure or pressure in combination with shear. The tolerance of soft tissue for pressure and shear may also be affected by microclimate, nutrition, perfusion, comorbid conditions, and condition of the soft tissue.

Mucosal Membrane Pressure Injury

Mucosal membrane pressure injuries are found on mucous membranes with a history of a medical device in use at the location of the injury. Because the staging system for cutaneous pressure injuries is based on the anatomy of skin, it cannot be used to stage mucosal pressure injury. These injuries are either partial thickness or full thickness.

Medical Device Related Pressure Injury

Medical device-related pressure injuries result from the use of devices designed and applied for diagnostic or therapeutic purposes. The resultant pressure injury generally conforms to the pattern or shape of the device. The injury should be staged using the staging system.

convatec

Adapted from NPIAP Pressure Injury Classification System[1]

STAGE 1

Non-Blanchable Erythema

Intact skin with a localized area of nonblanchable erythema, which may appear differently in darkly pigmented skin. Presence of blanchable erythema or changes in sensation, temperature, or fi rmness may precede visual changes. Color changes do not include purple or maroon discoloration; these may indicate DTPI.

STAGE 2

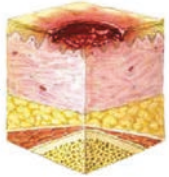

Partial Thickness Skin Loss

The wound bed is viable, pink or red, moist, and may also present as an intact or ruptured serum-fi lled blister. Adipose (fat) is not visible and deeper tissue is not visible. Granulation tissue, slough and eschar, are not present. These injuries commonly result from adverse microclimate and shear in the skin over the pelvis and shear in the heel.

STAGE 3

Full Thickness Skin Loss

Full-thickness skin loss, in which adipose (fat) is visible in the ulcer and granulation tissue and epibole (rolled wound edges), is often present. Slough and/or eschar may be visible. The depth of tissue damage varies by anatomical location; areas of significant adiposity can develop deep wounds. Undermining and tunneling may occur. Fascia, muscle, tendon, ligament, cartilage, or bone is not exposed. If slough or eschar obscures the extent of tissue loss, this is an unstageable pressure injury.

STAGE 4

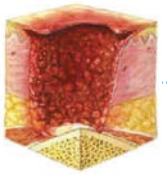

Full Thickness Skin and Tissue Loss

Full-thickness skin and tissue loss with exposed or directly palpable fascia, muscle, tendon, ligament, cartilage, or bone in the ulcer. Slough and/or eschar may be visible. Epibole (rolled edges), undermining, and/or tunneling often occur. Depth varies by anatomical location. If slough or eschar obscures the extent of tissue loss, this is an unstageable pressure injury.

UNSTAGEABLE FULL-THICKNESS PRESSURE INJURY

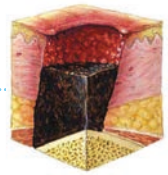

Full-thickness skin and tissue loss in which the extent of tissue damage within the ulcer cannot be confi rmed because it is obscured by slough or eschar. If slough or eschar is removed, a Stage 3 or Stage 4 pressure injury will be revealed. Stable eschar (ie, dry, adherent, intact without erythema or fluctuance) on ischemic limb or heels should not be softened or removed.

DEEP TISSUE PRESSURE INJURY

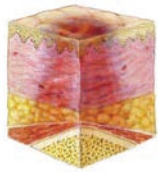

Intact or nonintact skin with localized area of persistent nonblanchable deep red, maroon, purple discoloration, or epidermal separation revealing a dark wound bed or bloodfilled blister. Pain and temperature change often precede skin color changes. Discoloration may appear differently in darkly pigmented skin. This injury results from intense and/or prolonged pressure and shear forces at the bone-muscle interface. The wound may evolve rapidly to reveal the actual extent of tissue injury or may resolve without tissue loss.*

convatec

*If necrotic tissue, subcutaneous tissue, granulation tissue, fascia, muscle, or other underlying structures are visible, this indicates a full-thickness pressure injury(unstageable, Stage 3, or Stage 4).

Do not use DTPI to describe vascular, traumatic, neuropathic, or dermatologic conditions.

Common Pressure Injury Locations[4]

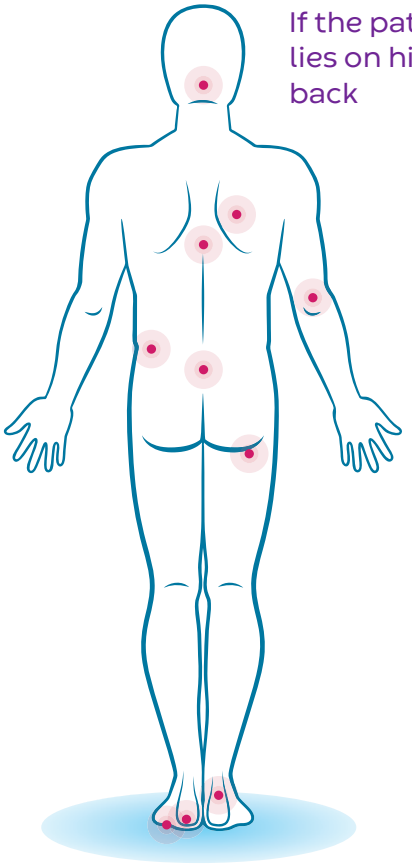

If the patient lies on his/her back

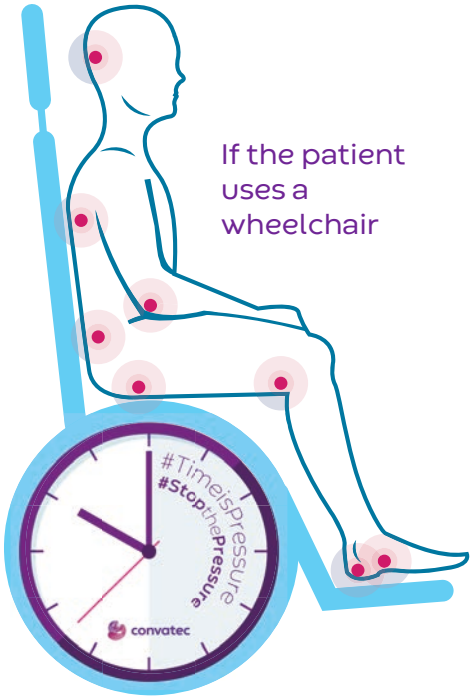

If the patient uses a wheelchair

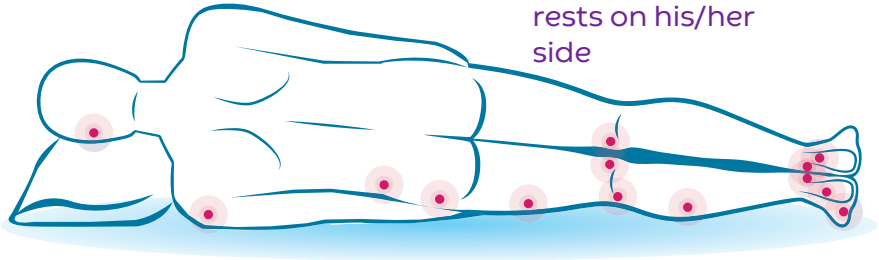

If the patient rests on his/her side

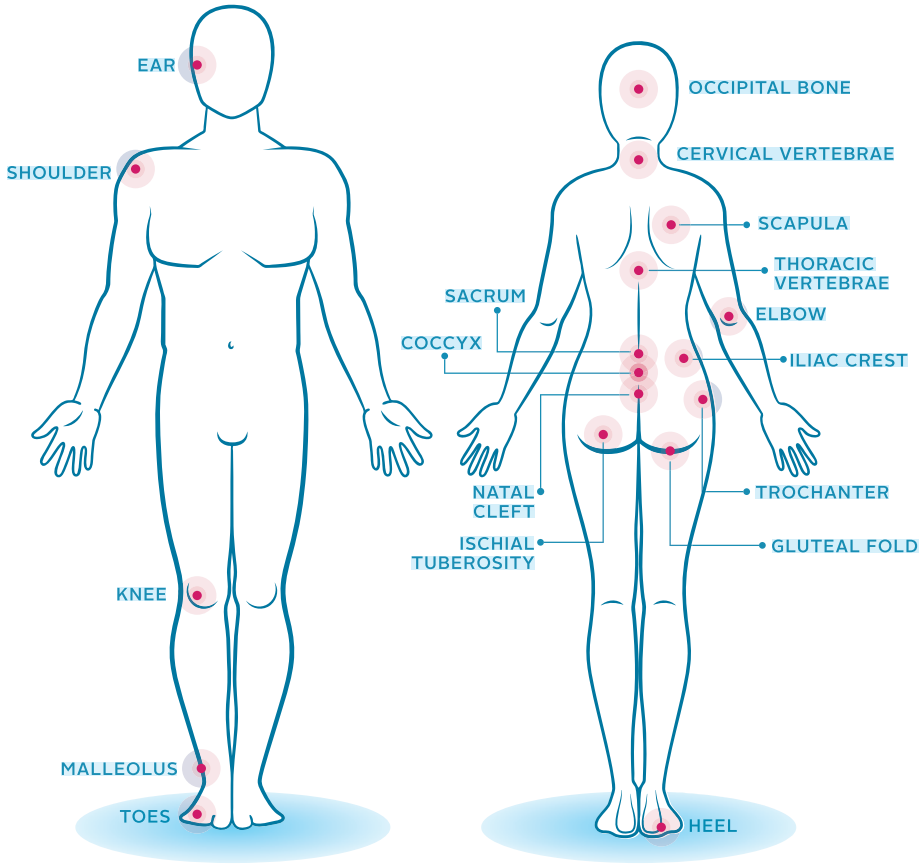

Although bony prominences are particularly susceptible to pressure injury development, they can develop on any soft tissue under prolonged pressure, e.g. from lying on a urinary catheter.

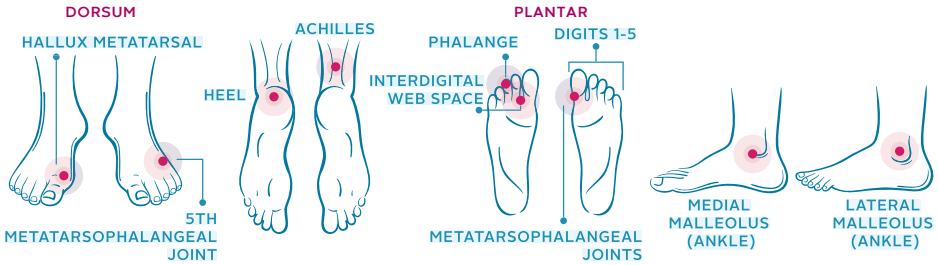

Moisture–Associated Skin Damage (MASD)

Moisture-Associated Skin Damage (MASD) is caused by prolonged exposure to various sources of moisture, including urine or stool, perspiration, wound exudate, mucus, saliva, and their contents.[5]

MASD can be caused by several conditions, including incontinence-associated dermatitis; intertriginous dermatitis; periwound moisture-associated dermatitis and peristomal moisture-associated dermatitis.[5] Identifying the cause can help to ensure appropriate prevention and management interventions are implemented.[6]

It is important to recognize the difference between MASD and pressure injuries. However, it is also vital to consider that once MASD occurs, there is a high risk of pressure injury development, as well as, increased risk of infection and morbidity.[5]

References

1. Edsberg, LE, Black, JM, Goldberg, M,McNichol, L, Moore, L, Sieggreen, M. Revised National Pressure Ulcer Advisory Panel pressure injury staging system. J Wound Ostomy Continence Nurs.2016; 43(6):1-13.
2. http://www.medetec.co.uk/files/medetec-images.html
3. Image supplied by Clinical Strategy Team, ConvaTec
4. ConvaTec Complete; Solutions® Algorithms for Wound Care, March 2007, E.R. Squibb & Sons, L.L.C. US-07-323
5. Gray, M, Black, JM, Baharestani, MM, et al. Moisture-associated skin damage: overview and pathophysiology. J Wound Ostomy Continence Nurs. 2011; 38(3):233-241.
6. Dowsett D, Allen L (2013) Moisture-associated skin damage made easy. Wounds UK 9(4). Available from: www.wounds-uk.com/made-easy

convatec
— forever caring —

www.convatec.com