The role of zirconia in the full mouth rehabilitation

By Michael N. Mandikos, BDSc (Hons), MS (New York), Cert Pros, FRACDS

The rapid proliferation of zirconia materials for conventional fixed restorations has been quite staggering. At the present time, there are more than seven major zirconia systems available to Australian clinicians. These systems typically utilise a CAD/CAM method to mill the restoration coping from a block of zirconia in its green state, which is then sinter-fired to produce the restoration coping. Layering ceramic is then applied to create the final restoration. Zirconia restorations are indicated as individual anterior and posterior crowns, bridges and implant abutments. The obvious question therefore presents: Can zirconia be used to restore a complete mouth?

Currently, all "true zirconia" systems appear to be enjoying very good clinical success, however some systems have a longer clinical record than others. In this case report, the author chose to use the 3M ESPE Lava zirconia system to restore all 28 teeth for this patient. The Lava system was chosen due to its excellent clinical fit,[1] very high strength,[2] and established clinical success[3] (the system has been in clinical use commercially for over 5 years). In Australia, the Lava system has a further advantage in that only Lava Ceram veneering porcelain is used on the zirconia copings. This ensures quality as the clinician receives a crown of known material composition, and the possibility of incompatible coefficients of thermal expansion

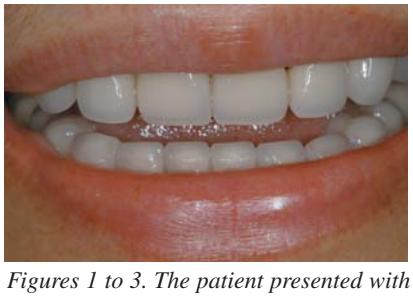

Figures 1 to 3. The patient presented with 28 units of PFM restorations which demonstrated poor morphology and contours. The crowns had been adjusted numerous times to improve the occlusal contact and the patient's comfort in occlusion. The patient was not satisfied with the appearance of her teeth and complained of frequent food-packing, as well as diurnal tiredness and aching in the masseter regions bilaterally. The vertical dimension of occlusion appeared to be too great.

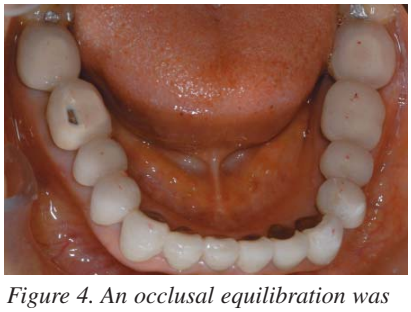

Figure 4. An occlusal equilibration was undertaken to improve balance and create initial stability in the bite. A new vertical dimension was established and impressions and a diagnostic wax-up were made.

Figures 5 and 6. The existing PFM restorations were removed. The underlying teeth demonstrated heavily tapered preparations but little evidence of prior caries or restoration that might have necessitated endodontics being performed in all 28 teeth.

Figures 7 to 9. Provisional restorations were made to the new occlusal scheme and adjusted progressively over a three month period until the patient was comfortable and happy with the aesthetics.

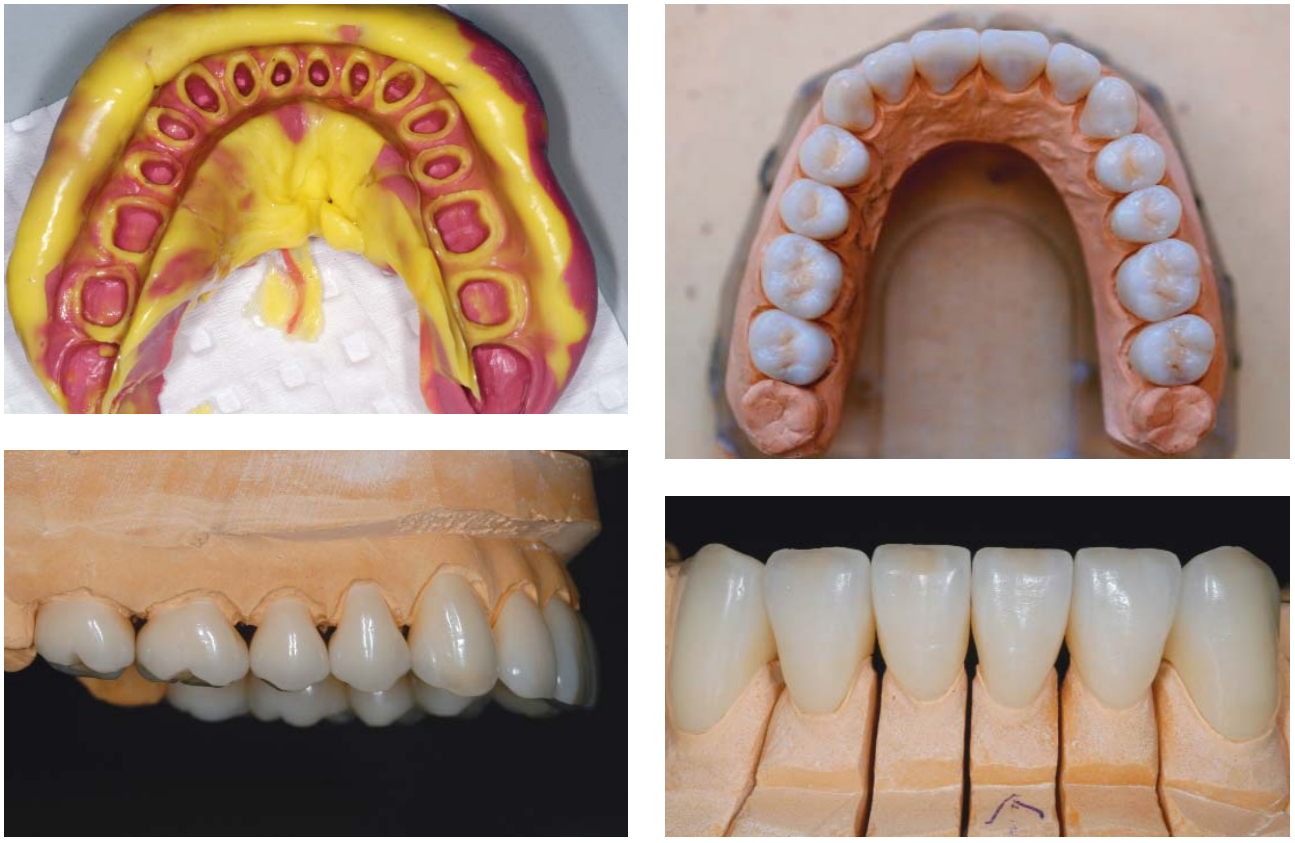

Figures 10 to 13. Impressions, jaw relation records, photographs and study models of the provisionals were made and sent to the ceramist. Lava all-ceramic zirconia crowns were made for all 28 teeth. Careful attention was paid to ensuring excellent, broad interproximal contact points were established.

(manifesting as porcelain delamination) or unfavourable wear properties are thus prevented. Lava crowns are the only fixed restoration provided with a full five year warranty in recognition of this quality.

In the present case report, the patient was a middle-aged female who had sought treatment overseas. Each of her teeth were endodontically treated and she was provided with 28 units of porcelain fused to metal restorations. The restorations were mostly over-contoured with light or open interproximal contact points, and many crowns demonstrated open margins. The patient was further unhappy with the comfort of her new bite, and equally unhappy with the aesthetic appearance. The crowns were approximately 12 months old at the time of her presentation.

After discussions with the patient and some endodontic re-treatment, replacement of the existing PFM restorations was undertaken. An extended provisional phase was utilised to test the comfort of the new occlusal scheme and to refine the aesthetics. Once the patient was satisfied with these provisional restorations, the final Lava zirconia restorations were made and cemented. The patient was very comfortable with her new occlusion and thrilled with the final aesthetic outcome.

It is not possible to describe in detail the stages of a full rehabilitation in a short case report. Accordingly, only the major steps have been highlighted. For clinicians further interested in this topic, a short course on "The Full Mouth Rehabilitation" will be co-presented by the author on 18-19 May 2007 at Surfers Paradise. Thanks also to Mr Yugo Hatai for his excellent ceramic work in this case.

Figures 14 and 15. The information developed by reviewing the patient and modifying her provisional restorations was used by the ceramist to carefully reproduce crowns that followed the occlusal and aesthetic guidelines already established clinically in the provisional phase.

Figures 16 and 17. The final restorations as they appeared immediately post-insertion. A comfortable and functional occlusion was established for the patient and the aesthetic result was a significant improvement over the presenting condition.

References

1. Reich et al. Clinical fit of all-ceramic three-unit fixed partial dentures, generated with three different CAD/CAM systems. Eur J Oral Science. 2005;113:174-79.

2. Piwowarczyk et al. A clinical report and overview of scientific studies and clinical procedures conducted on the 3M ESPE Lava All-Ceramic System. J Prosthodont 2005;14:39-45.

3. Raigrodski et al. The efficacy of posterior three-unit zirconium-oxide-based ceramic fixed partial dental prostheses: a prospective clinical pilot study. J Prosthet Dent 2006;96:237-44.

Disclosure: The author has a financial interest in Prestige Milling Services, a Lava Milling Centre.

Dr Michael Mandikos received his Bachelor of Dental Science Degree with honours, from the University of Queensland. He completed a three-year residency program at the State University of New York at Buffalo (USA), graduating with a Certificate in Prosthodontics and Masters Degree in Biomaterials in 1998. He has researched direct and indirect composite resins and he has published several papers in Australian and international journals on clinical and dental materials topics. Dr Mandikos has presented continuing education programs at dental meetings throughout Australia and Southeast Asia and is a Fellow of the Royal Australasian College of Dental Surgeons. He is a Visiting Specialist Prosthodontist to the University of Queensland Dental School and the Royal Australian Air Force. He is a reviewer for the Australian Dental Journal, Quintessence International and Clinica (International Journal of Brazilian Dentistry). Dr Mandikos is a product evaluator for several dental companies and he maintains a private practice limited to implant and Restorative Dentistry in Brisbane City.