The Laryngoscope

Temporalis Fascia Transplant for Vocal Fold Scar and Sulcus Vocalis

Michael J. Pitman, MD; Shaina M. Rubino, BA; Amy L. Cooper, MS, CCC-SLP

Objectives/Hypothesis: To evaluate vocal outcomes in 10 patients 1 year after autologous transplantation of temporalis fascia into Reinke's space (ATFV) for vocal fold scar and sulcus vocalis.

Study Design: Retrospective, clinical case series.

Methods: Subjective and objective evaluation was performed 12 months after surgery using laryngovideostroboscopy (LVS) in all patients, the Voice Handicap Index-10 (VHI-10) in seven patients, GRBAS (grade, roughness, breathiness, asthenia, strain) scale in nine patients, and noise-to-harmonics ratio (NHR), phonatory range (PR) and maximum phonation time (MPT) in six patients.

Results: LVS improved in all but one patient. A significant decrease was noted in the GRBAS subscales grade, roughness, asthenia, and strain ($P<.05$). Breathiness was almost significant, with a P value of .052. There was an average decrease in the VHI-10 of 8.14 ($P=.032$). NHR, MPT, and PR did not statistically improve.

Conclusions: ATFV for vocal fold scar and sulcus vocalis results in significant subjective vocal improvement that persists at least 1 year after surgery.

Key Words: Dysphonia, sulcus vocalis, vocal fold scar, autologous transplantation of temporalis fascia into the vocal fold.

Level of Evidence: 4

***Laryngoscope*, 124:1653–1658, 2014**

INTRODUCTION

Vocal fold scarring and sulcus vocalis result in significant dysphonia.[1] In such pathology the mucosa is deficient or disorganized.[2–5] As a result the mucosa is stiffened, inhibiting normal vocal fold vibration and phonation.[2,6,7] Much basic science and clinical research has been devoted to developing a successful therapy for this disorder. Despite this, an optimal treatment unfortunately does not exist. Conservative treatments, such as voice therapy and vocal fold injection augmentation, produce inconsistent and generally unsatisfactory results.[5,8] Multiple surgical techniques have been employed in the treatment of vocal fold scar.[7,9–14] The shear plethora of options is a testament to the challenge of this disorder and the absence of an optimal therapy. Though many of the techniques originally held promise, none withstood the test of time, as consistently good results have not been reproducible. In 2000, the autologous temporalis fascia transplant (ATFV) into Reinke's space was introduced as a new surgical option.[15] The same group reported good results with minimal complications in 10 patients after long-term follow-up.[16] Since this original description of the procedure, only one other study specifically evaluated the results of ATFV.[17] This study evidenced significant improvement in all 15 patients. ATFV is mentioned in three other reports, which are confounded by the inclusion of only two or three patients or the performance of ATFV in addition to vocal fold augmentation.[10,18,19]

Although the research of both Tsunoda and Pinto show promise for the use of ATFV, both investigations have deficiencies. Tsunoda included only maximum phonation time and stroboscopy findings as outcome measures.[16] Pinto included only subjective voice outcomes using an unrecognized linear grading scale of 1 to 5.[17] Considering the lack of an optimal treatment for vocal fold scar and sulcus vocalis, the promise of ATFV, the paucity of research on ATFV, and the shortcomings of previous investigations, we determined the need for the current study. The specific aim of this investigation was to conduct a retrospective study of the efficacy of ATFV 1 year after its employment in surgery for vocal fold scar and sulcus vocalis using accepted subjective and objective outcome measures of laryngeal function, vocal quality, and voice handicap.

MATERIALS AND METHODS

This study is a retrospective review of patients who were treated with ATFV into Reinke's space for dysphonia secondary to sulcus vocalis or vocal fold scar. The study was approved by the *institutional review board* of the New York Eye and Ear Infirmary. Diagnosis was assumed during laryngovideostroboscopy (LVS), suggested by a combination of spindle glottal gap, vibratory edge furrows, or impaired mucosal wave. All patients were treated with voice therapy preoperatively. Two patients

From the Division of Laryngology M.J.P. and Department of Communicative Disorders A.L.C., The Voice and Swallowing Institute, New York Eye and Ear Infirmary, New York, New York; and New York Medical College S.M.R., Valhalla, New York, U.S.A

Editor's Note: This Manuscript was accepted for publication November 25, 2013.

Presented as a poster at the American Laryngological Association, Combined Otolaryngology Spring Meeting, Orlando, Florida, U.S.A., April 11, 2013.

The authors have no funding, financial relationships, or conflicts of interest to disclose.

Send correspondence to Michael J. Pitman, MD, Associate Professor, Director, Division of Laryngology, The Voice and Swallowing Institute, New York Eye and Ear Infirmary, 310 East 14th Street, New York, NY 10003. E-mail: mpitman@nyee.edu

DOI: 10.1002/lary.24536

TABLE I.
List of the Vocal Fold Abnormalities for Each Patient.

Patient	Diagnosis
A	Type 2 sulcus vocalis, bilateral
B	Type 2 sulcus vocalis, bilateral
C	Type 2 sulcus vocalis, bilateral
D	Vocal fold scar, bilateral
E	Vocal fold scar, bilateral
F	Type 2 sulcus vocalis, bilateral
G	Type 2 sulcus vocalis, bilateral
H	Type 2 sulcus vocalis, bilateral
I	Type 2 sulcus vocalis, right
J	Type 2 sulcus vocalis, bilateral

Type of sulcus was recorded as per the strict definition by Ford et al.[7] Scar was defined as a sclerotic disturbance of the vocal fold cover inconsistent with sulcus but demonstrating adherence of the epithelium to the vocal ligament without elevation in response to subepithelial infusion during direct laryngoscopy.

had a temporary micronized Alloderm injection a minimum of 3 months prior to surgery. Neither management resulted in acceptable vocal improvement, and patients were deemed candidates for ATFV; informed consent was obtained. The diagnosis was confirmed by adherence of the epithelium to the vocal ligament without elevation in response to subepithelial infusion during direct laryngoscopy. The abnormality was classified as sulcus vocalis as defined by Ford et al.[7] It was classified as scar if the cover was sclerotic but inconsistent with the strict definition of a sulcus (Table I). All patients who underwent the procedure at the New York Eye and Ear Infirmary and had at least 1 year of follow-up were included in the study. All surgeries were performed by the senior author (M.P.) between November 2009 and August 2012. Surgeries were performed as unilateral or bilateral as dictated by pathology, in the fashion described by Tsunoda et al.[16] On the third patient, a partial herniation of the graft was noted despite suture closure of the incision. This resulted in the only modification of the surgical procedure, with placement of fibrin glue over the incision in addition to suturing the incision closed. All patients subsequent to this had the fibrin glue applied. Postoperative physician visits occurred at 5 days, 1 month, 3 months, 6 months, and 12 months following the procedure. Patients underwent 4 to 6 weekly sessions of postoperative voice therapy. LVS, laryngeal function testing, Voice Handicap Index-10 (VHI-10), and the GRBAS (grade, roughness, breathiness, asthenia, strain) rating were performed within 1 month prior to surgery and 12 months postoperatively.[20,21]

Of the 10 patients included in the study, voice samples were collected preoperatively and 12 months postoperatively in nine patients. The samples were coded, randomly ordered, and graded blindly using the GRBAS scale by two reviewers, a laryngologist (M.J.P.) and speech language pathologist (A.L.C.). Each sample was graded twice by each individual on a scale of 0 to 3, 0 being normal and 3 indicating severe dysfunction. The individual scores given by the two reviewers for each category of assessment (grade, roughness, breathiness, asthenia, and strain) were averaged and recorded as the five GRBAS subscale values for a given voice sample (Table II). The average preoperative and 1-year values for each subscale across all the patients were compared using a paired t test. Due to the small sample size, prior to using the t test throughout this investigation, Kolmogorov-Smirnov and Shapiro-Wilk tests of normality were performed to confirm that none of the variables departed significantly from normality. Mauchly's test demonstrated there was not a statistically significant departure from sphericity. A repeated measures analysis of variance was then used to confirm that within subjects there was no significant difference between the GRBAS variables.

VHI-10 questionnaires were collected preoperatively and 12 months postoperatively in seven patients (Table II). The questionnaires were filled out by the patients immediately prior to their scheduled medical evaluation. The average preoperative VHI-10 was compared using a paired t test to the average postoperative VHI-10.

Noise-to-harmonics ratio (NHR), phonatory range (PR), and maximum phonation time (MPT) were assessed preoperatively and 12 months postoperatively in six patients (Table III). Microphone and electroglottography (EGG) recordings were obtained for a series of vocal tasks. Participants wore an AKG model C555L microphone (AKG Acoustics GmbH, Vienna, Austria) at a distance of 3 cm from the commissure of the lips during all tasks. The EGG signal was monitored on an oscilloscope to assess signal quality. Segments of data chosen for analysis were selected based on visual inspection. The data were collected using Computerized Speech Laboratory, Multi-

TABLE II.
Subjective Voice Evaluation.

	G		R		B		A		S		VHI-10	
Patient	Pre	Post	Pre	Post	Pre	Post	Pre	Post	Pre	Post	Pre	Post
A	1.5	1	1	1.5	1.25	0.5	1.75	0.5	1.75	1	NP	NP
B	2.75	2.5	2.75	2.5	1.5	2	1.5	1	2	2	28	1
C	1.5	0.5	1.25	0.5	1	0	1.5	0	1.25	0	15	9
D	2	1	1.75	0.5	1.5	1	1.25	1	1.75	1	25	17
E	3	1	3	1.25	1.75	0.5	1.75	1	2.5	0.75	31	29
F	2.25	2	2.5	2	1.5	1	1.5	0.5	2	1.5	16	NP
G	1	NP	1.25	NP	0.75	NP	0.75	NP	0.75	NP	35	NP
H	2.25	1	1.25	1	1.25	0.5	1.25	0.5	1.75	1	19	7
I	1.25	1.5	1.5	1.5	0.75	1	1	1	0.5	1	22	17
J	2.5	2	2	1.5	2	2	2.5	2	3	1.5	27	30

Preoperative (Pre) and 12-month postoperative (Post) GRBAS and VHI. GRBAS scores were provided by two evaluators for each subject. These scores were averaged to determine each final subscale score.

GRABAS = grade, roughness, breathiness, asthenia, strain; NP = not performed; VHI = Voice Handicap Index-10.

TABLE III.
Objective Voice Evaluation.

Patient	Maximum Phonation Time		Phonatory Range		Noise/Harmonic Ratio	
	Pre	Post	Pre	Post	Pre	Post
A	10	12.5	10	8	0.12	0.11
B	7	10	31	14	0.2	0.12
C	10.2	18	18	15	0.14	0.14
D	5	14	16	13	0.29	0.15
E	NP	7	NP	11	NP	0.2
F	NP	NP	NP	NP	NP	NP
G	13	NP	NP	NP	0.12	NP
H	13.8	15	9	26	0.122	0.13
I	NP	4.7	NP	NP	NP	0.1
J	10.7	5.2	26	24	0.129	0.2

Preoperative (Pre) and postoperative (Post) testing complete for six patients.

NP = not performed.

Dimensional Voice Program Model 5105 (KayPENTAX, Montvale, NJ). The average preoperative and postoperative values for each test were compared using a paired *t* test.

The videos of LVS performed preoperatively and 12 months postoperatively were reviewed by MP. The presence of a mucosal wave was evaluated and scored: 0 = absent, 1 = present but reduced, and 2 = normal. The glottal gap was characterized using standard nomenclature.

RESULTS

NHR, PR, and MPT included a small sample and did not show statistically significant change (Table IV).

There was an average decrease in the VHI-10 of 8.14 ($P = .032$) (Table V). Closer evaluation of the change in VHI-10 per patient revealed improvement in six of the seven patients who completed a preoperative and 12-month postoperative VHI-10 (Fig. 1).

Subjective professional voice assessment using the GRBAS scale evidenced a mean decrease of 0.633 after the five GRBAS values were grouped into a single GRBAS average variable ($P = .005$). A significant decrease was noted in the individual subscales grade, roughness, asthenia, and strain ($P < .05$). Breathiness neared significance with a P value of .052 (Table V).

All but one patient had bilateral grafting performed. As a result, 19 vocal folds were treated (Table VI). Sixteen of 19 vocals folds demonstrated an improvement in mucosal wave. Seven postoperative vocal folds displayed a normal mucosal wave, whereas the other nine had a wave that was present but reduced from normal. Preoperatively, only one vocal fold had displayed a mucosal wave (patient J). In this patient, despite the preoperative LVS findings, a sulcus was noted on subepithelial infusion during surgery, and a decision was made to place a graft in this vocal fold as well. Glottal closure improved in nine of 10 patients. The closure for patient F was unchanged. Although patient G displayed a spindle gap pre- and postoperatively, the gap was significantly smaller postoperatively.

All procedures were performed without intraoperative complication. One patient appeared to have a partial postoperative extrusion of the graft with a resultant granuloma 1 week after surgery. This resolved by 8 weeks.

DISCUSSION

Vocal fold scar and sulcus vocalis are characterized by fibrosis and disorganization of the mucosa.[2–4] This results in a stiff vocal fold with dysphonia, poor mucosal vibration, incomplete glottal closure, and significant vocal handicap.[1,2,6] The resultant voice is often characterized as hoarse, asthenic, with vocal strain, fatigue, and decreased projection.[6,7] Voice therapy is generally unsuccessful, as it does not address the anatomic abnormalities of the vocal folds.[5] Surgical treatment of these disorders is extremely difficult and results are variable. Procedures generally address either the glottal insufficiency or the stiff vocal fold cover. To address the glottal insufficiency, vocal fold medialization via type-1 laryngoplasty or injection augmentation have been employed. Excision of the sulcus or scar, mucosal slicing technique, undermining and release of scar, injection of steroids, photoangiolytic laser treatment, and fat implantation into Reinke's space are used to address the poor vocal fold vibration.[9,11–14,22,23] Unfortunately, the vocal improvement is marginal and inconsistent.[8–10] Due to the inconsistent and often unsatisfactory results, investigation for alternative surgical methods was performed and revealed the ATFV as described by Tsunoda et al. in 2000 and their long-term follow-up results in 2005.[15,16] Though they had performed 30 such cases by 2005, they reported on 10 patients who had follow-up of at least 3

TABLE IV.
Statistical Evaluation of Objective Voice Evaluations.

	Paired Differences					
	Mean	Standard Deviation	Standard Error of the Mean	95% Confidence Interval of the Difference		Significance (2-Tailed)
				Lower	Upper	
NHRpost-NHRpre	−0.02517	0.07403	0.03022	−0.10286	0.05253	.443
Prpost-Prpre	−1.66667	10.83820	4.42468	−13.04066	9.70733	.722
MPTpost-MPTpre	3.00000	5.19192	2.11959	−2.44858	8.44858	.216

Preoperative (pre) and 12-month postoperative (post) values for laryngeal function measures in six patients.

TABLE V.
Subjective Voice Evaluation.

	Paired Differences					
	Mean	Standard Deviation	Standard Error of the Mean	95% Confidence Interval of the Difference		Significance (2-Tailed)
				Lower	Upper	
Gpost-Gpre	−0.72222	0.66667	0.22222	−1.23467	−0.20978	.012
Rpost-Rpre	−0.52778	0.66667	0.22222	−1.04022	−0.01533	.045
Bpost-Bpre	−0.44444	0.58333	0.19444	−0.89283	0.00395	.052
Apost-Apre	−0.72222	0.47507	0.15836	−1.08740	−0.35705	.002
Spost-Spre	−0.75000	0.70711	0.23570	−1.29353	−0.20647	.013
VHIpost-VHIpre	−8.14286	9.54688	3.608380269	7.916587243	8.369127043	.032

Statistical analysis of preoperative (pre) and 12-month postoperative (post) Voice Handicap Index-10 (VHI-10) scores for seven patients and individual GRBAS (grade, roughness, breathiness, asthenia, strain) subscale scores averaged across nine patients. The VHI-10 and all GRBAS subscales demonstrate significant improvement except for breathiness, which nears significance.

years. The surgical technique was meticulously described. Stroboscopic evaluation revealed restoration of mucosal wave in all patients by 1 year. MPT, an indirect measure of glottal competency, showed a slow but dramatic increase in all patients by 6 months, with seven of 10 patients experiencing further increase at 1 year. The improvement was maintained for all patients at 3 years and was statistically significant when compared to preoperative measures. Subjective and laryngeal function testing outside of MPT were not performed.

Three complications were reported in 30 cases. One patient experienced expulsion of the graft within 1 week postoperatively. This resulted in adding a suture closure to the vocal fold incision. Two included partial herniation of the graft. In the first case, this resulted in the formation of granulation tissue. As a result, on the second occurrence, the herniated fascia was excised seven days postoperatively, preventing granuloma formation.[16,24] This excised graft was studied histologically and compared to freshly harvested fascia grafts. Histologic staining of fascia grafts at harvest showed collagen and a small amount of fibroblasts with no Ki-67 staining (a marker of cellular proliferation). In comparison, the specimen excised 7 days postoperatively displayed a dramatic increase in cellular components and Ki-67, confirming proliferative activity. The authors suggested that improvement in vocal fold function after ATFV may be due to metaplasia stimulated by the proliferating fibroblasts and possibly stem cells of the temporalis fascia graft.

Only four other publications mention the use of ATFV for the treatment of vocal fold sulcus or scar.[10,17–19] Tan et al. reported on two patients who were treated with ATFV.[18] One case was complicated by complete extrusion of the graft. The other patient was noted to be improved at 1.5 months postoperatively, but the details of this evaluation are not apparent. Welham et al. reported on 10 patients who underwent grafting into Reinke's space for sulcus vocalis or vocal fold scar.[10] Only three of the 10 had ATFV, whereas the other seven had Alloderm grafted, making conclusions difficult. Both types of grafts were performed without complication and resulted in an improved VHI-10. No improvement was noted in auditory-perceptual, acoustic, aerodynamic, or vocal fold physiologic performance. The authors stressed the actuality of a prolonged recovery time for graft patients of 18 months before achieving maximal improvement. Hsiung et al. reported on 22 patients.[19] Their outcomes were complicated by the fact that all patients received ATFV and fat injection augmentation. Sixteen, three, and three patients, respectively, reported vocal outcomes as excellent, improved, and the same, with a mean follow-up of 16.6 months. Acoustic parameters did not show significant improvement. Maximum phonation time, grade, roughness, breathiness, mucosal wave, and amplitude were all significantly improved. The study by Pinto et al. is the only study aside from Tsunoda et al. that reports on a significant number of patients who underwent only ATFV.[17] They reported on 15 patients. Using an unrecognized linear grading scale of 1 to 5, all patients experienced an improvement in professional perceptual voice analysis as well as in the patients' own evaluation. As with other investigations, acoustic parameters did not show significant improvement.

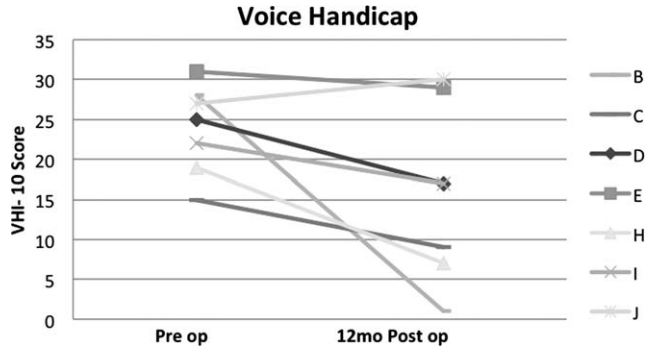

Fig. 1. Change in Voice Handicap Index-10 (VHI-10) for seven patients. The one patient who was significantly worse, patient J, had a complication of partial graft extrusion with granulation formation and significant vocal fold inflammation. Post op = postoperative; Pre op = preoperative.

TABLE VI.
Laryngovideostroboscopy Evaluation.

	Pre			Post		
	Wave			Wave		
Patient	R	L	Closure	R	L	Closure
A	0	0	Irregular	2	1	Touch closure
B	0	0	Spindle	2	1	Posterior gap
C	0	0	Spindle	2	2	Full
D	0	0	Irregular	1	1	Full
E	0	0	Irregular	1	1	Full
F	0	0	Spindle	0	0	Spindle
G	0	0	Spindle	1	1	Spindle
H	0	0	Spindle	2	2	Full
I	0	2	Spindle	2	2	Full
J	1	0	Spindle	1	1	Posterior gap

Preoperative (Pre) and 12-month postoperative (Post) mucosal wave and glottal closure. R = Right vocal fold, L = Left vocal fold. Mucosal wave: 0 = absent, 1 = present but reduced, 2 = normal.

Considering the absence of an optimal therapy for vocal fold sulcus and scar as well as the small amount of unconfounded data on the efficacy of ATFV, we aimed to review the outcome of our patients with at least 1-year follow-up using objective acoustic parameters and accepted scales for evaluation of vocal quality and voice handicap.

As with other studies, improvement in acoustic parameters was not shown. In this study, only six patients had preoperative and 12-month postoperative studies, resulting a small number of patients, which may have affected the statistical outcome.

Professional perceptual voice analysis of all 10 patients using the GRBAS scale showed significant improvement overall and in all subscales except breathiness. The P value for breathiness equaled .052 and trended towards significance. One may suggest that with a larger sample size this value would become significant as well.

Patient self-assessment of vocal handicap using the VHI-10 evidenced significant improvement 1 year after surgery ($P = .032$). Only one patient had an increase in their VHI-10, from 27 to 30. This patient experienced the lone complication of in the study, partial extrusion of the graft with granuloma formation. Inflammation of the surgical site was severe and resolved by 8 weeks. Healing in this particular case was prolonged and the ultimate outcome for this patient was increasing dysphonia.

The complication of graft extrusion is not isolated to our study.[16,18] Extrusion or herniation of the graft appears to be the main complication of ATFV. Concomitant granuloma formation may cause a prolonged recovery or a poor outcome. After this case, all incisions were sealed with fibrin glue in addition to the typical suture closure. No further complications or graft extrusions were noted, and this dual closure is recommended.

The LVS displayed improvement in nine of the 10 patients in both mucosal wave and glottal closure. Patient F did not improve in either category. Despite this, the patient still had improvement in all GRBAS categories. A 12-month VHI-10 was not performed. It appears that ATFV results in improvement in both glottal closure and in mucosal wave in most cases. This finding suggests ATFV is well suited for the treatment of sulcus and scar where deficiencies in both areas impact vocal production.

Though not specifically evaluated in this investigation, clinically it appeared the majority of vocal improvement took place 2 to 6 months postoperatively. In the first postoperative month the patients were severely dysphonic. This slow recovery is noted by other authors and is the primary deficiency with ATFV.[10,16] Patients must be counseled on this issue. Considering the significant vocal improvement in all of our patients, except one who had a complication, the similar success of other authors performing ATFV and the highly variable outcome of other surgical options, ATFV should be considered a very good option for treatment despite the prolonged recovery time. An alternative graft that allows quicker recovery would be optimal, but one does not currently exist.

CONCLUSION

Vocal fold sulcus and scar results in significant dysphonia. Many surgical options result in unsatisfactory and inconsistent outcomes. In the large majority of patients, ATFV results in an improved mucosal wave and glottal closure, subjective vocal improvement, and decreased patient vocal handicap. The main risk of complication is herniation of the fascia graft with granuloma formation, possibly resulting in a poor outcome. The placement of fibrin glue over the vocal fold incision in addition to the usual suture closure should minimize this risk. Despite a longer vocal recovery time, ATFV is a very good option for treatment of vocal fold scar and sulcus vocalis.

ACKNOWLEDGMENTS

The authors acknowledge Rosanna Gutierrez for the demanding roll of patient coordinator.

BIBLIOGRAPHY

1. Welham NV, Dailey SH, Ford CN, Bless DM. Voice handicap evaluation of patients with pathologic sulcus vocalis. *Ann Otol Rhinol Laryngol* 2007; 116:411–417.
2. Thibeault SL, Gray SD, Bless DM, Chan RW, Ford CN. Histologic and rheologic characterization of vocal fold scarring. *J Voice* 2002;16:96–104.
3. Rousseau B, Hirano S, Scheidt TD, et al. Characterization of vocal fold scarring in a canine model. *Laryngoscope* 2003;113:620–627.
4. Hirano S, Minamiguchi S, Yamashita M, Ohno T, Kanemaru S-I, Kitamura M. Histologic characterization of human scarred vocal folds. *J Voice* 2009;23:399–407.
5. Hirano S. Current treatment of vocal fold scarring. *Curr Opin Otolaryngol Head Neck Surg* 2005;13:143–147.
6. HIrano M, Yoshida T, Tanaka S, Hibi S. Sulcus vocalis: functional aspects. *Ann Otol Rhinol Laryngol* 1990;99(9 pt 1):679–683.
7. Ford CN, Inagi K, Khidr A, Bless DM, Gilchrist KW. Sulcus vocalis: a rational analytical approach to diagnosis and management. *Ann Otol Rhinol Laryngol* 1996;105:189–200.
8. Remacle M, Lawson G. Results with collagen injection into the vocal folds for medialization. *Curr Opin Otolaryngol Head Neck Surg* 2007;15: 148–152.
9. Shah RN, Deal AM, Buckmire RA. Multidimensional voice outcomes after type I Gore-Tex thyroplasty in patients with nonparalytic glottic incompetence. *Laryngoscope* 2013;123:1742–1745.
10. Welham NV, Choi SH, Dailey SH, Ford CN, Jiang JJ, Bless DM. Prospective multi-arm evaluation of surgical treatments for vocal fold scar and pathologic sulcus vocalis. *Laryngoscope* 2011;121:1252–1260.

11. Pontes P, Behlau M. Treatment of sulcus vocalis: auditory perceptual and acoustical analysis of the slicing mucosa surgical technique. *J Voice* 1993;7:365–376.
12. Mallur PS, Gartner-Schmidt J, Rosen CA. Voice outcomes following the gray minithyrotomy. *Ann Otol Rhinol Laryngol* 2012;121:490–496.
13. Remacle M, Lawson G, Degols JC, Evrard I, Jamart J. Microsurgery of sulcus vergeture with carbon dioxide laser and injectable collagen. *Ann Otol Rhinol Laryngol* 2000;109:141–148.
14. Bouchayer M, Cornut G, Witzig E, Loire R, Roch JB, Bastian RW. Epidermoid cysts, sulci, and mucosal bridges of the true vocal cord: a report of 157 cases. *Laryngoscope* 1985;95(9 pt 1):1087–94.
15. Tsunoda K, Niimi S. Autologous transplantation of fascia into the vocal fold. *Laryngoscope* 2000;110:680–682.
16. Tsunoda K, Kondou K, Kaga K, et al. Autologous transplantation of fascia into the vocal fold: long-term result of type-1 transplantation and the future. *Laryngoscope* 2005;115(12 pt 2 suppl 108):1–10.
17. Pinto JA, da Silva Freitas MLA, Carpes AF, Zimath P, Marquis V, Godoy L. Autologous grafts for treatment of vocal sulcus and atrophy. *Otolaryngol Head Neck Surg* 2007;137:785–791.
18. Tan M, Bassiri-Tehrani M, Woo P. Allograft (Alloderm) and autograft (temporalis fascia) implantation for glottic insufficiency: a novel approach. *J Voice* 2011;25:619–625.
19. Hsiung M-W, Kang B-H, Pai L, Su W-F, Lin Y-H. Combination of fascia transplantation and fat injection into the vocal fold for sulcus vocalis: long-term results. *Ann Otol Rhinol Laryngol* 2004;113:359–366.
20. Hirano M. Clinical Examination of Voice. New York, NY: Springer-Verlag; 1981.
21. Rosen CA, Lee AS, Osborne J, Zullo T, Murry T. Development and validation of the voice handicap index-10. *Laryngoscope* 2004;114: 1549–1556.
22. Mortensen M. Laryngeal steroid injection for vocal fold scar. *Curr Opin Otolaryngol Head Neck Surg* 2010;18:487–491.
23. Mortensen MM, Woo P, Ivey C, Thompson C, Carroll L, Altman K. The use of the pulse dye laser in the treatment of vocal fold scar: a preliminary study. *Laryngoscope* 2008;118:1884–1888.
24. Tsunoda K, Baer T, Niimi S. Autologous transplantation of fascia into the vocal fold: long-term results of a new phonosurgical technique for glottal incompetence. *Laryngoscope* 2001;111:453–457.